

## Atrioventricular Groove Rupture After Mitral Valve Replacement in A Patient With Atrial Fibrillation Secondary to Rheumatic Cardiopatia: Case Report

Romero-Sánchez Alan Jesús<sup>1</sup>, Carreto Salazar María Ivonne<sup>2</sup>, Pérez-Dolores Andrea Kimberly<sup>3</sup>, Lozano-Rueda Giancarlo<sup>4</sup>

<sup>1,2,3,4</sup>Instituto Mexicano del Seguro Social, Medical Unit of High Specialty No. 14, Veracruz.

### ABSTRACT

**Introduction:** Atrioventricular sulcus lesion (AVGD) is a catastrophic complication of mitral valve surgeries that occurs in less than 2% of the population, with a mortality of 90%. Left ventricular rupture after mitral valve (MVR) replacement should be diagnosed immediately and repaired without hesitation. There are numerous complications described and known after MVR, such as thromboembolism, structural valve degeneration and endocarditis, paravalvular leakage, conduction irregularities in the pathway and bleeding.

**Case presentation:** We present the case of a female patient with a history of rheumatic heart disease with double mitral injury and atrial fibrillation, in which severe mitral stenosis was documented with ECOTT reflecting thrombi of heterogeneous appearance occupying almost entirely left atrium. Programmed for left auriculotomy, valve replacement and thrombus exceresis, resulting in the procedure lesion of the atrioventricular groove meriting packing of the same and placement of mediastinal probes, with subsequent admission to post-surgical coronary care unit.

**Conclusions:** At present, atrioventricular groove rupture is a rare event with increased mortality, the incidence depends on age and associated risk factors in the patient, In our case, rheumatic heart disease generates arrhythmias as a procoagulant state. Although the rupture can be repaired in a second surgical time, follow-up and post-operative care require comprehensive medical equipment and continuous hemodynamic surveillance.

**KEYWORDS:** Case report, atrioventricular groove rupture, rheumatic heart disease, mitral valve replacement.

### ARTICLE DETAILS

**Published On:**  
**12 August 2023**

**Available on:**  
<https://ijmscr.org/>

### 1. INTRODUCTION

Atrioventricular sulcus lesion (AVGD) is a catastrophic complication of mitral valve surgery that occurs in less than 2% of the population, with 90% mortality. <sup>(1)</sup>

Depending on the start time of the rupture, it can be classified as early rupture (which takes place in the operating room), late rupture (which occurs in hours or days) and late rupture (which occurs days or years after MVR and presents as a pseudoaneurysm). <sup>(2)</sup>

Breaks are classified into three types according to the location of the tear site. Type I rupture is located in the atrioventricular groove, type II rupture is at the base of the posterior papillary muscle, and type III rupture occurs midway between type I and II sites. Type I is the most common type and can be seen

in the highly calcified mitral valve ring, the pathological finding is the separation of the fibrous skeleton ring from the heart with blood extravasations to the myocardium and ultimately frank perforation and rupture. The result of type I rupture is worse than type II. This high mortality is due to the anatomical location of the rupture that requires a specific surgical approach and a close trajectory of the left circumflex coronary artery, which can be sutured and lead to myocardial infarction. <sup>(3)</sup>

Successful management of a type I atrioventricular groove rupture in a protocolized patient for left auriculotomy and mitral valve implantation is described, using extracorporeal circulation and correcting the defect with 48-hour packaging

## Atrioventricular Groove Rupture After Mitral Valve Replacement in A Patient With Atrial Fibrillation Secondary to Rheumatic Cardiopatia: Case Report

and a mixed pericardial patch, with appropriate postoperative results in coronary intensive care unit.

### 2. PRESENTATION OF THE CASE

We present the case of a 56-year-old patient with a history of inactive rheumatic heart disease with double mitral injury; Atrial fibrillation in management with acenocumarina and amiodarone, with a register of cardioembolic cerebral vascular event in the right middle cerebral artery, with motor sequelae of the left hemibody, RANKIN 3. Hypothyroidism in treatment with levothyroxine. Assessed by clinical cardiology service for rheumatic heart disease, with progressive dyspnea in increase of functional class NYHA IV.

Left atrium echocardiogram was performed with measurements of 78x49 mm, right atrium: 64x36 mms,

inferior vena cava: 21mm - collapse of 50%. VD: 39x18x32. FEVI 88 %, FAC 52 %, TAPSE 24 mms. severe dysfunction type filling pattern. Mitral valve: thickened. AVM 0.86 cm without failure. golf club sign, thickened valves with non-assertable aperture limitation with aortic insufficiency, concluding severe diastolic dysfunction by large atrial dilation. Moderate to severe mitral stenosis AMV 0.86 GRAD MED 7 severe biauricular dilation.

Transesophageal echocardiogram was performed showing double mitral lesion, thickened leaflets, calcified with dome opening and hockey stick image (Figure 1), with moderate insufficiency, severe AV stenosis 0.8cm by THP, GP 33 mmHg, mean 12 mmHg in addition to thrombi of heterogeneous appearance that occupy almost completely left atrium

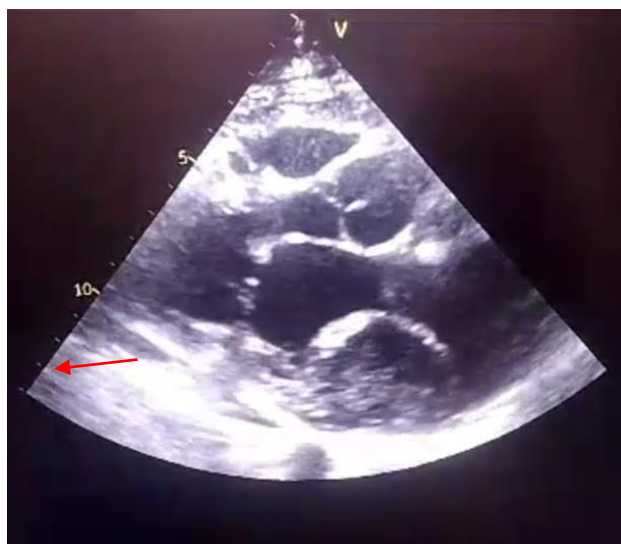

Figure 1.

As part of the pre-surgical process, catheterization was performed without angiographic lesions in coronary arteries. It was protocolized for mechanical mitral valve implantation and left atrial thrombus exceresis.

Left auriculotomy was performed, showing severe thickening of mitral subvalvular apparatus with giant thrombus in the left atrium occupying 80% with posterior exceresis. Mechanical mitral valve implant 27 mm Medtronic was placed, with pump time 67 minutes and aortic impingement of 56 minutes, at the point of release to complete AV block, temporary epicardial pacemaker was placed, DCP output at the first attempt, with hemostasis review documenting active bleeding in a layer from the posterior atrioventricular sulcus, hemostatic sealant type BIOGLUE was placed, warranting

packing of the atrioventricular sulcus with a compress in a hammock as well as 7 gauze, managing to contain the bleeding, placing two permeable mediastinal probes.

Patient admitted for severity criteria in coronary intensive care unit taking one week in the same. During his stay in the unit, he was supported by double vasopressors, inotropics and transfusions of hemocomponents due to mixed shock criteria. After the first surgery, unpacking was performed (Figure 2) at 48 hours, of 1 compress and 7 gauze, with 100cc bleeding, in the revision of the posterior atrioventricular groove, was observed without bleeding, noting infiltration of the groove with non-bleeding hematoma (Figure 3), allowed apex contractility and left ventricular lateral face, preserved right ventricular contractility.

## Atrioventricular Groove Rupture After Mitral Valve Replacement in A Patient With Atrial Fibrillation Secondary to Rheumatic Cardiopatia: Case Report

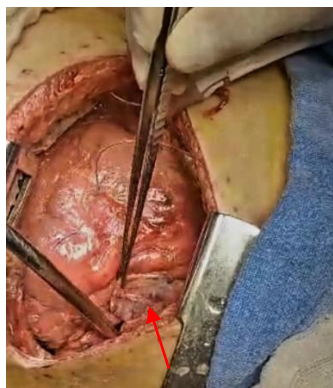

Figure 2.

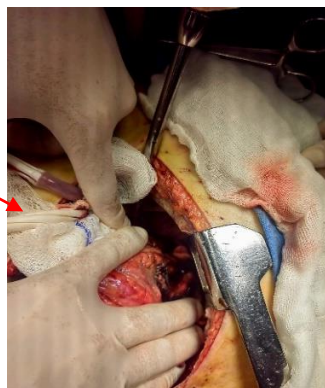


Figure 3.

Secondary to reintervention was maintained with mechanical ventilation for 2 more days with subsequent successful weaning, removal of mediastinal probes and pericardial pacemaker, as well as vasopressor support achieving mean blood pressure (GPA) perfusoria, adjusts anticoagulant management and is discharged to floor Cardiology.

### 3. DISCUSSION OF THE CASE

Our case report shows an infrequent transoperative complication, addressing in an integral way the general context of our patient, since it had important comorbidities for the development of the same, an arrhythmia as a basic pathology, which translated the formation of a coagulum of uncommon characteristics. In our scenario, advanced age stands out, providing tissues with greater friability and calcifications in rings, complicating the procedure itself.

Age is a risk factor for AV groove rupture due to the higher incidence of annular calcification and friable tissues. Preservation of the posterior leaflet and basal cords may help prevent AV rupture, but this is not always possible.<sup>(3)</sup>

Elderly patients have a more friable myocardium and more severe mitral annular calcification in mitral stenosis. Once broken, treatment is difficult and results in high mortality and morbidity for the patient.<sup>(4)</sup>

Decalcification of the mitral ring is an essential component of rupture in patients with calcified mitral valve disease, extensive decalcification is at risk of interrupting the AV groove, leading to potentially irreparable heart injury.<sup>(5)</sup>

Therefore, the rupture of the left ventricle after mitral valve (MVR) replacement should be immediately diagnosed and repaired without hesitation.<sup>(3)</sup>

Spontaneous rupture has been associated with elevated left atrial pressure and overdistension, elevated tension in the atrioventricular groove at the time of ejection and use of inotropic agents.<sup>(6)</sup>

There are numerous complications described and known after MVR, such as thromboembolism, structural valve degeneration and endocarditis, paravalvular leakage, conduction irregularities in the pathway and bleeding.<sup>(5)</sup>

Different techniques were included as part of the treatment of the lesion, observing a mixed approach with internal, external repairs and sealant applications during the procedure, which

showed an adequate therapeutic effectiveness with translation in the hemodynamic state of the patient.<sup>(7)</sup>

The most recommended procedure is internal repair, which consists of implanting a patch inside the cardiac cavity with subsequent implantation of a prosthesis in a second time. The mechanism of injury has changed dramatically over time, elderly patients present a disproportionate degree of friable tissue, have a decreased tolerance to prolonged surgical periods.<sup>(1)</sup>

Several repair techniques have been described with different success rates; However, the rarity of the complication prevents consensus on the safest technique.<sup>(8)</sup>

Large amounts of hemostatic agents have been successfully used, such as a combination of fibrin sheets, fibrin glue and gelatin glue, resorcin and formalin. Application of BioGlue type adhesive under an intracardiac patch has also been described.<sup>(9)</sup>

The most commonly used approaches for mitral valve surgery are the right atrial septum approach or the atrial atrial sulcus approach, which can achieve satisfactory exposure in most cases<sup>(10)</sup>; However, in special cases, such as patients with a small left atrium, pericardial adhesions, or deep thorax, it may be difficult to obtain satisfactory exposure with the conventional approach.<sup>(11)</sup>

Beyond standard internal and external repair techniques, supplementation has been tried as a way to achieve adequate hemostasis, achieving variable success.<sup>(12)</sup>

Although there are different techniques as part of the treatment of the injury, in our patient with mitral valve injury, mediastinal packing was decided as the technique of choice to contain acute bleeding for 48 hours in which our patient merits double vasopressor therapy for a state of secondary obstructive shock due to cardiac tamponade as a consequence placement of compresses and mediastinal gauze, after 48 hours in which it was decided to remove packaging, a hematoma was observed in the posterior interventricular groove without residual bleeding so it was decided to repair stereotomy by remitting the shock state, This technique showed an adequate therapeutic effectiveness with translation into hemodynamics of the patient reducing short-term mortality.

# Atrioventricular Groove Rupture After Mitral Valve Replacement in A Patient With Atrial Fibrillation Secondary to Rheumatic Cardiopatía: Case Report

## 4. CONCLUSION

At present, atrioventricular groove rupture is a rare event with high mortality rates, incidence depends on age and associated risk factors in the patient, In our case, rheumatic heart disease generates arrhythmias as a procoagulant state.

A complete repair is often not enough to prevent a catastrophic outcome, although the rupture can be repaired in a second surgical time, follow-up and post-surgical care require a comprehensive medical team and continuous hemodynamic surveillance.

## AUTHOR CONTRIBUTION

**Conceptualization:** Romero-Sánchez Alan Jesús, Carreto Salazar María Ivonne, Pérez-Dolores Andrea Kimberly Lozano-Rueda Giancarlo.

**Research:** Romero-Sánchez Alan Jesús, Carreto Salazar María Ivonne, Pérez-Dolores Andrea Kimberly

**Methodology:** Pérez-Dolores Andrea Kimberly, Romero-Sánchez Alan Jesús, Carreto Salazar María Ivonne, Lozano-Rueda Giancarlo.

**Visualization:** Pérez-Dolores Andrea Kimberly, Romero-Sánchez Alan Jesús, Carreto-Salazar María Ivonne

## REFERENCES

- I. Dobrilovic, N., Raman, J., Fingleton, J. G., Maslow, A., & Singh, A. K. (2017). Long-term outcomes of external repair as a rescue operation for atrioventricular groove disruption. *The Annals of thoracic surgery*, 103(2), 491-496.
- II. Sousa AIC, Gonçalves AMGS, Madureira AJBS, Almeida JMS, Torres JMLP. Marked mitral prosthesis rocking motion preceding atrioventricular groove rupture. *J Cardiol Cases*. 2014 Oct 18;11(1):25-27. doi: 10.1016/j.jccase.2014.09.004. PMID: 30546529; PMCID: PMC6280011.
- III. Raevsky E, Kwanten L, Cullen S, Stoica S. Repair of atrioventricular disruption after mitral valve replacement utilizing commando procedure principles. *Interact*.
- IV. Kwon JT, Jung TE, Lee DH. The rupture of atrioventricular groove after mitral valve replacement in an elderly patient. *J Cardiothorac Surg*. 2014 Feb 8;9:28. doi: 10.1186/1749-8090-9-28. PMID: 24506935; PMCID: PMC3922257.
- V. *Cardiovasc Thorac Surg*. 2022 Jul 9;35(2):ivac179. doi: 10.1093/icvts/ivac179. PMID: 35775927; PMCID: PMC9270861.
- VI. Guerrero, A. F., Valero, W., Tavera, A., Obando, C. E., Camacho, J., & Giraldo, J. C. (2016). Atrioventricular disruption after mitral valve replacement reoperation: repair and echocardiographic evaluation. *Revista Colombiana de Cardiología*, 23(4), 333-e1.
- VII. Antonic M, Djordjevic A, Mohorko T, Petrovic R, Lipovec R, Juric P. Left ventricular pseudoaneurysm following atrioventricular groove rupture after mitral valve replacement. *SAGE Open Med Case Rep*. 2019 Jan 12;7:2050313X18823456. doi: 10.1177/2050313X18823456. PMID: 30719310; PMCID: PMC6349977.
- VIII. Durukan AB, Serter FT, Gurbuz HA, Tavlasoglu M, Ucar HI, Yorgancioglu C. Biological glue application in repair of atrioventricular groove rupture: a case report. *J Tehran Heart Cent*. 2014;9(3):137-9. Epub 2014 Jul 3. PMID: 25870633; PMCID: PMC4393838.
- IX. Abel SA, Stark TA, Rehfeldt KH, Rihal CS, Said SM. Modified Cabrol Shunt for Atrioventricular Groove Rupture After Mitral Valve Replacement. *Ann Thorac Surg*. 2018 Jan;105(1):e11-e13. doi: 10.1016/j.athoracsur.2017.07.044. PMID: 29233353. (9 was made 8))
- X. Chen, F., Wang, X., Zhuang, X. y Guo, H. (2022). Mitral anuloplasty with approach of left atrial atrial sulcus-dome in a patient with Marfan syndrome. *Journal of Cardiothoracic Surgery*, 17 (1), 293.
- XI. Ciro Mancilha Murad and others, Late atrioventricular groove disruption presenting 7 years after mitral valve replacement: a case report, *European Heart Journal - Case Reports*, Volume 4, Issue 3, June 2020, Pages 1–5, <https://doi.org/10.1093/ehjcr/ytaa091>
- XII. Karlson KJ, Ashraf MM, Berger RL. Rupture of left ventricle following mitral valve replacement. *Ann Thorac Surg*. 1988 Nov;46(5):590-7. doi: 10.1016/s0003-4975(10)64712-1. PMID: 3190341.