

Paraquat Poisoning in a Female in the Fourth Decade of Life

Mayra Evelyn Quiñones Martínez¹, Jose Jesus Zarur Bartolome², Kim Rodriguez Relingh³

^{1,2,3}Department of Internal Medicine High Specialty Hospital of Veracruz, Sesver, Veracruz, Mexico Av.20 De Noviembre 1074 Ver, Ver

ABSTRACT

This case report is about a woman in her fourth decade of life who, after a fight, went into a nervous-depressive crisis and decided to consciously ingest the herbicide paraquat. The patient is from a rural community and after 6 hours she decided to go to a tertiary level hospital located in the nearest city due to the persistence of her discomfort. In the emergency room she reported having consumed about 300 milliliters of paraquat, the effects were not immediate, but after 5 hours she began with asthenia, adynamia, sialorrhea, she was hospitalized for 10 days presenting the three phases described, starting with the gastrointestinal phase, the hepatorenal phase where on the fourth day after ingestion there was a peak elevation of hepatic transaminases and azo levels and the pulmonary phase causing a type of pulmonary lesion, since the alveolar spaces were filled with microhemorrhages. In this third level hospital, support care, hydration and medication were provided according to the literature, but despite the excessive amount consumed and the high mortality rate of this type of intoxication, it had an unfavorable end..

ARTICLE DETAILS

Published On:
21 June 2023

Available on:
<https://ijmscr.org/>

INTRODUCTION

Paraquat is a bipyridyl herbicide that acts by contact, it is presented in liquid form in concentrations of 20% for agricultural use. Its chemical name is 1-1'-dimethyl-4-4'-bipyridyl¹⁻². It is frequently used in agricultural areas. It has been available to farmers for more than 40 years and is the second most sold agrochemical in the world. Paraquat's herbicidal properties were discovered in 1955 and the active ingredient was introduced on world markets in 1962 under the brand name GRAMOXONE®, available as a 20 or 40% aqueous solution^{2,3,4}

The lungs are the first target of paraquat, and pulmonary effects represent the most lethal and least treatable manifestation of toxicity. However, inhalation toxicity is rare. The primary mechanism is the generation of free radicals that oxidize lung tissue⁵⁻⁶. Although acute pulmonary edema and lung damage can occur within hours after severe acute exposures^{7,8}, the delayed toxic injury of pulmonary fibrosis, the usual cause of death, most commonly occurs 7 to 14 days after ingestion.⁹ In some patients who ingested a large amount of concentrated form (20%), they died more rapidly due to circulatory failure (within 48 hours). Both type I and II pneumocytes appear to selectively accumulate paraquat. Biotransformation of paraquat in these cells generates free

radicals, resulting in lipid peroxidation and cell damage. Hemorrhage, edema fluids and leukocytes infiltrate the alveolar spaces, after which fibroblast proliferation immediately appears. There is a progressive decrease in arterial oxygen tension and CO₂ diffusion capacity. Such a deterioration in gas exchange causes the progressive proliferation of fibrous connective tissue in the alveoli causing finally death by asphyxia and tissue anoxia.¹⁰

CLINICAL CASE

Female patient in her fourth decade of life began her current illness on March 28th during the afternoon with conscious consumption of paraquat herbicide of approximately 300 ml, immediately presented nausea and abdominal pain, 4 hours later she presented vomiting on 10 occasions of gastrointestinal content and 10 liquid evacuations. Afterwards, he consumed a medicinal herb known as (crucetillo) as an antidote, asthenia, adynamia and sialorrhea were added to the clinical picture, as he did not show improvement he went to the emergency area of the hospital 8 hours after ingestion, on admission treatment was started with analgesic, fluid therapy and proton pump inhibitor, a referral to the intensive care unit was requested, which referred the patient to the gastroenterology department, which evaluated the patient and mentioned that he would not benefit from

Paraquat Poisoning in a Female in the Fourth Decade of Life

endoscopy due to the time of evolution and risk of perforation, During her stay on the internal medicine floor we were able to see elevation of liver enzymes in the first two days, acute renal injury after ingestion, she was kept hydrated, because

she did not have a window period for the use of activated carbon, she was treated conservatively.

Paraclinical evolution

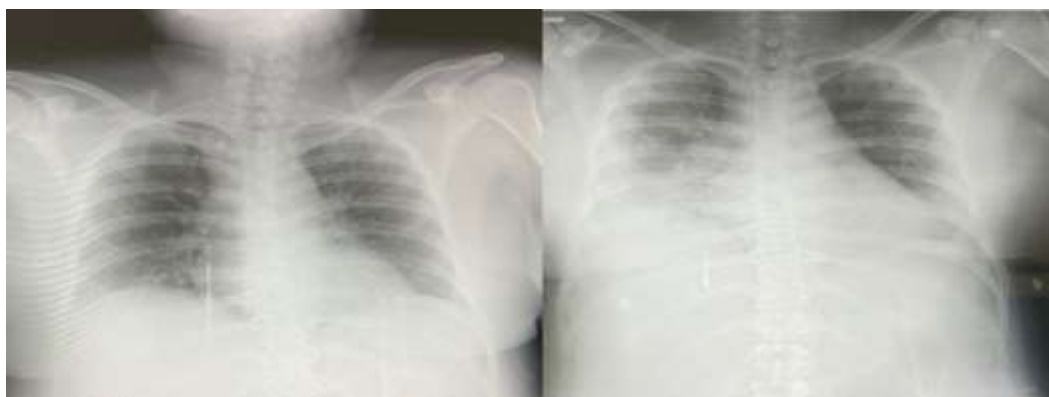
	28.03.23	29.03.23	30.03.23	31.03.23	03.03.23	10.04.23
AST	77	173	126	288	97	73
ALT	78	175	210	443	307	79
BT	1.80	5.50	5.90	6	11.30	5.30
BD	0.80	3.70	4.50	4.50	8	4.20
UREA	72.8	100	132	205	137	121.9
CR	3.87	5.23	5.90	5.30	3.09	4.90

At 48 hours of laboratory evolution we observed an increase in hepatic transaminases, acute kidney injury grade 3, since there is an increase of more than three times the baseline value, clinically the patient already had icteric coloration in skin and integuments, as well as pain at the level of the hepatic border at mid and deep palpation, the patient had hydration and use of steroid via vein.

At 96 hours post-exposure is when we found the maximum point of elevation of hepatic transaminases, with persistence of acute renal injury, at this time the patient begins with febrile peaks >39°C, reaching convulsions on 2 occasions. After 144 hours post ingestion of paraquat, a decrease in

hepatic transaminase levels and improvement in the azotemia were observed, but clinically the patient continued to be clinically unstable, with persistent fever, requiring the use of supplemental oxygen.

On the 8th day of intrahospital stay, a central blood culture was performed where they found the presence of *Staphylococcus haemolyticus*, sensitive to tetracyclines, the patient was in very good health, although laboratorially there was a significant decrease in hepatic transaminations and renal function, due to the high morbidity that this type of intoxication has, taking into account the amount that the patient took, she died on the 10th day of intrahospital stay



A

B

Figure 1. Images A and B of the second and fifth day of hospitalization, A) shows cardiac silhouette in normal limits, with pleuropulmonary transparency, no pleuropulmonary syndrome or bone alterations, B) shows an effacement of the right costodiaphragmatic angle, suggestive of pleural effusion, secondary to a probable chemical pneumonia due to the use of supplemental oxygen.

DISCUSSION

Paraquat dichloride is an effective and widely used herbicide that has a proven safety record when properly applied to kill weeds. However in recent decades numerous deaths have occurred mainly through accidental or voluntary ingestion¹⁰ In the context of paraquat poisoning, most cases are suicidal ingestion, some accidental, which have been seen in children or adults in a state of inebriation, but homicidal etiology is always important to rule out¹¹.

The WHO recommended classification of pesticides by hazard was approved by the 28th World Health Assembly in 1975 and has since gained wide acceptance. The original guidelines approved by the World Health Assembly in 1975 were followed unchanged until 2009, when the World Health Organization classified Paraquat as a "Moderately hazardous technical grade active ingredient (Class II) in pesticides"¹². Just one teaspoon of concentrated Paraquat can cause death in an adult human being, since the estimated minimum lethal

Paraquat Poisoning in a Female in the Fourth Decade of Life

dose is about 30mg/kg or 3-6g of Paraquat ion, which is equivalent to 10-20ml of 20% solution¹³.

Medical experience has elaborated an approximate dose-effect ratio scale by which the prognosis of cases of paraquat ingestion can be made:

- Less than 20 mg of ionic paraquat per kg body weight (less than 7.5 ml of 20% w/v paraquat concentrate). No symptoms or only gastrointestinal symptoms are present. Recovery is likely.

- 20 to 40 mg ionic paraquat per kilogram body weight (7.5 to 15.0 ml 20% [w/v] paraquat concentrate). Lung fibroplasia appears. In most cases death ensues, which may be delayed for 2 to 3 weeks.

- More than 40 mg of ionic paraquat per kilogram body weight (more than 15.0 ml at 20% [w/v] paraquat concentrate). Multiple organ damage occurs as in class II, but progresses more rapidly. It is often characterized by marked ulceration in the oropharynx. Mortality is generally 100%, within 1 to 7 days¹⁴.

Most Paraquat poisonings result from ingestion. Paraquat is known to be absorbed very rapidly, apparently associated with the transporter-mediated choline transport system in the brush border membrane, although this absorption from the gastrointestinal tract is low. Absorption occurs mainly in the small intestine (little of the stomach) and is estimated to be 1

5% in humans over a period of 1 to 6 hours. Any recent ingestion of food may decrease the amount of systemic absorption. Although the maximum plasma time is not known with certainty in humans, paraquat can be detected in urine as soon as 1 h after ingestion¹⁰. Paraquat is rapidly but incompletely absorbed and then eliminated largely unchanged in the urine within 12 to 24 hours.

Paraquat-induced toxicity and its clinical characteristics are due to its ability to undergo redox cycling and subsequent generation of intracellular reactive oxygen species that cause cellular damage through lipid peroxidation, nuclear factor kappa B activation, mitochondrial damage and apoptosis, since the generation of highly reactive oxygen species and nitrite produces toxicity in most organs, but toxicity is particularly severe in the lungs, as paraquat is absorbed against a concentration gradient in the lung leading to pneumonitis and pulmonary fibrosis. Paraquat also damages the heart, kidneys, liver, adrenal glands, central nervous system, muscles and spleen, leading to multi-organ failure^{13,14}.

Despite the proposed treatment variation, the reported lethality is very high in all centers, and mortality varies between 50% and 90%, but in cases of intentional auto-intoxication with concentrated formulations, mortality approaches 100%¹⁴.

Clase	DL ₅₀ para la rata (mg/kg de peso corporal)	
	Oral	Dérmica
Ia Sumamente peligroso	< 5	< 50
Ib Muy peligroso	5 - 50	50 - 200
II Moderadamente peligroso	50 - 2000	200 - 2000
III Poco peligroso	Más de 2000	Más de 2000
U Poco probable que presente un peligro agudo	5000 o más	

REFERENCES

- I. Gisbert - Calabuig . J. Medicina Legal y Toxicología .(2001) Quinta edición. Editorial Massón . Barcelona, España. 2001. 925-928.
- II. Eduardo Vargas Alvarado. Medicina Legal. (2007). 2da. Edición- México :Trillas . Páginas 401-403.
- III. Nogué , S.; Dueñas, A. (2000). Intoxicación por paraquat : un puzzle al que le faltan piezas. Med Clin (Barc). 115, 546-8.
- IV. López, AM ; Rivero , C.; Galbán , C.; Marino, A.; Piñeiro , N.; Ferrer , E. (2002). Intoxicaciones por paraquat y hemoperfusión con carbón activado . An Med Interna. 19, 310-2.
- V. Pond SM. Manifestations and management of paraquat poisoning. Med J Aust 1990;152:256-9.
- VI. Giulivi C, Lavagno CC, Lucesoli F, et al. Lung damage in paraquat poisoning and hyperbaric oxygen exposure: superoxide-mediated inhibition of phospholipase A2. Free Radic Biol Med 1995;18:203-13.
- VII. Nordquist RE, Nguyen H, Poyer JL, et al. The role of free radicals in paraquat-induced corneal lesions. Free Radic Res 1995;23:61-71.
- VIII. Honore P, Hantson P, Fauville JP, et al. Paraquat poisoning: State of the art. Acta Clin Belg 1994;49:220-8.
- IX. Bismuth C, Garnier R, Dally S, et al. Prognosis and treatment of paraquat poisoning: A review of 28 cases. J Toxicol Clin Toxicol 1982;19:461-74
- X. R.J Dinis-Oliveira, J.A. Duarte, A. Sanchez-Navarro, F Remiao, M. L. Bastos & f. Carvalho. Paraquat Poisonings: Mechanisms of Lung Toxicity, Clinical Features, and Treatment Critical Reviews in Toxicology Volume 38, 2008
- XI. Viales López, G. (2014). Intoxicación por

Paraquat Poisoning in a Female in the Fourth Decade of Life

paraquat. *Medicina Legal de Costa Rica*, 31(2), 88-94.

- XII. World Health Organization. (2010). "The WHO recommended classification of pesticides by hazard and guidelines to classification 2009". Disponible en <http://bcn.cl/2ckbr> (Diciembre 2019).
- XIII. Mohammad Delirrad, Mohammad Majidi, Behzad Boushehri. Clinical features and prognosis of paraquat poisoning: a review of 41 cases. *Int J Clin Exp Med* 2015;8(5):8122-8128
- XIV. Gawarammana IB and Buckley NA. Medical management of paraquat ingestion. *Br J Clin Pharmacol* 2011; 72: 745-757