

## Parotid Gland Adenocarcinoma: A Case Report

M. Yamsun<sup>1</sup>, Ariska Pranastiara Putri Eliana<sup>2</sup>

<sup>1</sup>Department of Surgery, Faculty of Medicine, Jenderal Soedirman University, Purwokerto, Indonesia

<sup>2</sup>Faculty of Medicine, Jenderal Soedirman University, Purwokerto, Indonesia

---

### ABSTRACT

Adenocarcinoma no otherwise specified (NOS) and polymorphous low-grade adenocarcinoma (PLGA), are malignant tumors of the salivary glands. Both types of malignant tumors have the potential for recurrence and distant metastases. Rare cases of recurrence and metastases lead to the absence of standardized systemic therapy for salivary gland cancer. This case report aims to expand the literature regarding recurrence and distant metastases of parotid gland adenocarcinoma. We report the case of a 54-year-old woman who complained of a recurrent lump in the right mandibular area who had previously undergone chemoradiotherapy, right parathyroidectomy, and left mastectomy. Histopathological examination of the biopsies that were performed gave different results, namely adenocarcinoma and PLGA.

**KEYWORDS:** adenocarcinoma no other specified, polymorphous low-grade adenocarcinoma, parotid gland, metastases, recurrence

---

### ARTICLE DETAILS

**Published On:**  
**10 May 2023**

**Available on:**  
**<https://ijmscr.org/>**

---

### INTRODUCTION

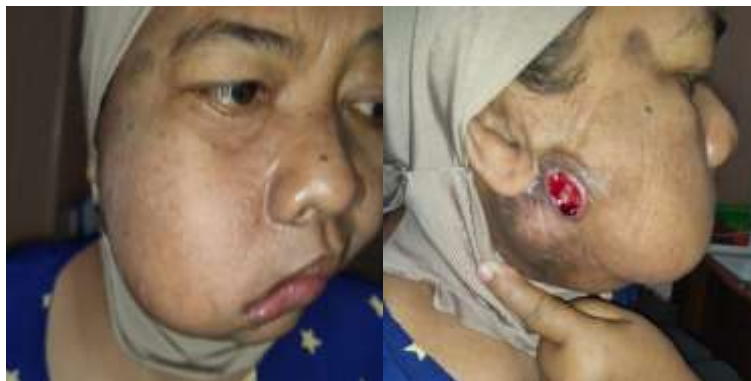Adenocarcinoma no otherwise specified (NOS) is a malignant tumor of the salivary glands. Histologically in adenocarcinoma NOS will be seen duct formation without any specific morphology and/or immunohistochemistry. These tumors can involve major (60%) and minor (40%) salivary glands. In 60% of cases, the tumor occurs in the parotid gland, with a peak incidence in the 6th decade<sup>6</sup>. Meanwhile, polymorphous adenocarcinoma (PAC), or previously known as polymorphous low-grade adenocarcinoma (PLGA), is a rare salivary gland neoplasm. The incidence is only 0.051 cases per 100,000 people annually<sup>4</sup>. 90% of cases arise in the minor salivary glands, rarely in the major salivary glands<sup>8</sup>. PAC is found more often in women than men with a ratio of 2:1, and the average occurs at the age of 59 years (16-94 years). Metastases are rare, both lymphatic and hematogenous<sup>3</sup>. 10% of the total cases show metastases to the lymph nodes and recurrence is reported to reach 5-33%<sup>8</sup>. Histologically, PAC can resemble adenoid cystic carcinoma (AdCC) and has an infiltrative growth pattern with a mixed solid, cribriform, tubular, and cystic

pattern. Solid variant AdCC is the most aggressive type and has a tendency to metastasize hematogenously in 40-60% of cases<sup>9</sup>. In this study, we present one case of adenocarcinoma of the parotid gland which had both distant metastases and recurrence.

### CASE REPORT

On Tuesday, January 17<sup>th</sup> 2023, a 54-year-old woman came to the Surgical Oncology polyclinic at Margono Soekardjo Hospital complaining of a lump in her right lower jaw that felt painful and itchy. The patient is known to have a history of biopsies on the right parotid gland 3 times and removal of the left breast. The patient's blood pressure is 123/78 mmHg, pulse is 98 x/min, respiration is 20 x/min, and temperature is 36.9 °C. The cheek looks asymmetrical, there is a lump on the right lower jaw with a size of 10 x 6 cm, and ulceration with a size of 4 x 2 cm is visible. The lump feels hard and is fixed with the surrounding tissue. The lump has been felt since 1 year ago. Currently the patient is receiving Exemestane treatment.

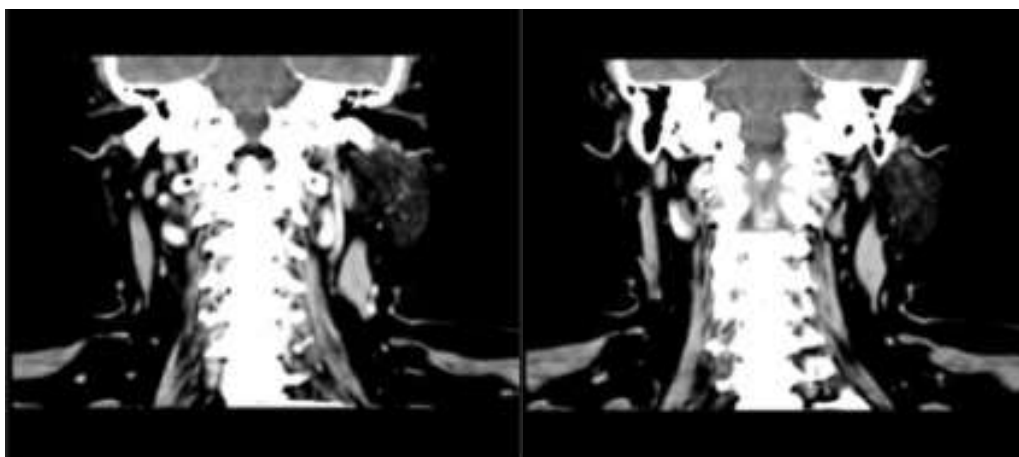
## Parotid Gland Adenocarcinoma: A Case Report



**Figure 1. Clinical photo of the patient**

The patient had previously experienced the same complaint, a lump in the lower right jaw in 2014, and had a biopsy done at the Cilacap Hospital. The results obtained from the biopsy examination were adenocarcinoma of the right parotid. Then the patient was referred to Margono Soekardjo Hospital and underwent 6 chemotherapy procedures with Cisplatin. In 2015, a lump reappeared in the same area, the patient complained of pain and itching. The lump grew bigger and

felt harder, and then a parathyroidectomy was performed in July 2016. The biopsy results revealed a polymorphous low-grade adenocarcinoma. The patient then received radiotherapy 35 times. In October 2018, the patient underwent an MSCT scan of the paranasal sinuses with contrast and found an impression of colli dextra reactive lymphadenopathy measuring 1.4 x 0.8 x 0.7 cm.

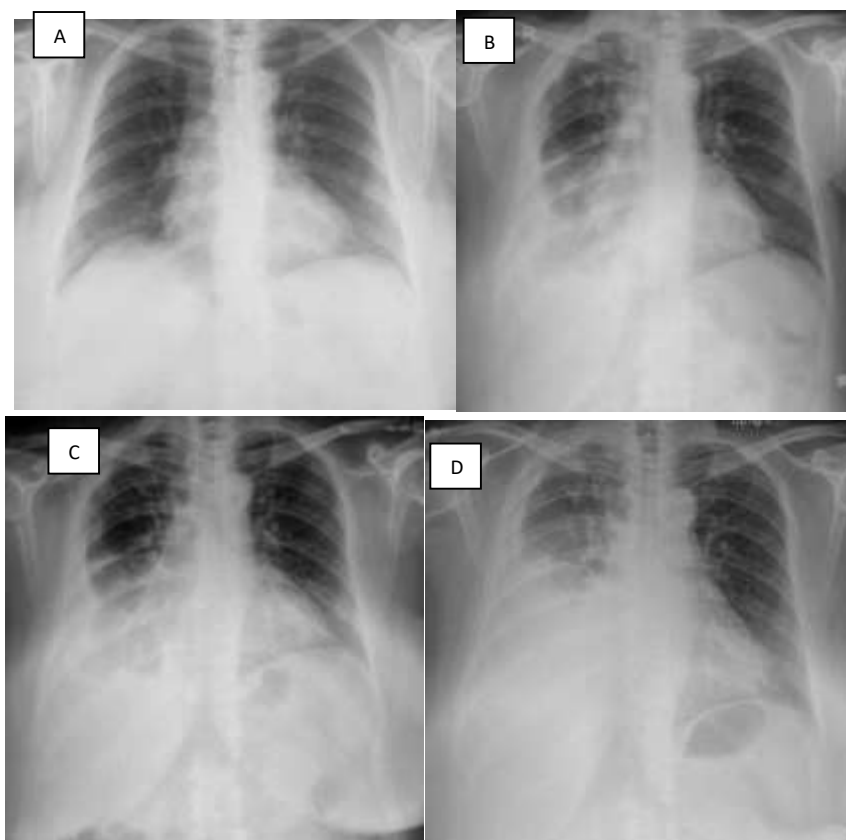


**Figure 2. MSCT scan of the paranasal sinuses with contrast**

In October 2021, the patient returned to the Margono Soekardjo Hospital with complaints of a painful lump in her left breast. In November 2021, the patient also complained of a new lump appearing on her right cheek near his chin. After a biopsy of the breast lump was performed, the results obtained were grade III invasive ductal carcinoma mammae. Immunohistochemical examination yielded ER +3, PR +3, Her2 +2, and Ki67 +. At that time the patient had a right

pleural effusion, so a WSD was installed and no atypical cells were found on examination. In December 2021, the patient started receiving Exemestane treatment. The patient also underwent a mastectomy in the same month and a histopathological examination was performed, with the results of invasive carcinoma mammae of no special type grade II lymph node metastases.

## Parotid Gland Adenocarcinoma: A Case Report



**Figure 3. Chest X-ray of the patient (A: September 10<sup>th</sup> 2018, B: November 3<sup>rd</sup> 2021, C: December 27<sup>th</sup> 2021, D: May 11<sup>th</sup> 2022)**

In April 2022, there was a new lump on the right cheek that was painful. Then in May 2022 a biopsy was carried out and on examination it was found that the right parotid adenocarcinoma was moderately differentiated. The wound was still wet until the last control. The patient continues to be given Exemestane therapy which is taken once a day. In addition, the patient received additional therapy in the form of an antibiotic ointment to treat the wound.

### DISCUSSION

Adenocarcinoma not otherwise specified (NOS) of the salivary glands is a highly malignant tumor. Histologically in adenocarcinoma NOS will be seen ducts or glands without specific morphology and/or immunohistochemistry. High-grade tumors will show density (solid) and pleomorphism. These tumors can occur in all salivary glands, both major and minor, with a predilection for the parotid glands. Recurrence and distant metastases may occur, with the most frequently involved organs being the lung, bone, and brain<sup>6</sup>.

Meanwhile, polymorphous adenocarcinoma (PAC) is a type of malignant tumor known primarily as a minor salivary gland tumor in the soft palate, and rarely occurs in the parotid. The tumor is histologically similar to adenoid cystic carcinoma (AdCC), the most common malignant tumor of the salivary glands. The incidence of AdCC metastases to lymph nodes is low. Nonetheless, local recurrence is common. In addition, distant metastases may occur in 30% to 40% of patients years later and usually involve the lungs<sup>2</sup>.

Histological parameters that increase the risk of distant metastases are tumor size, grade, presence of lymph node involvement, and local spread to the surrounding soft tissue, such as facial nerve disturbance and vascular invasion. Large tumor size has a significant correlation with the occurrence of distant metastases. High-grade tumors have a metastatic rate that is twice as high as low-grade tumors. The presence of involved regional lymph nodes increases the risk 3.4 times of developing distant metastases<sup>6</sup>.

Not many studies have shown the existence of distant metastases from malignant tumors of the salivary glands. A study found that out of 301 subjects, 57 of them had distant metastases, with the organs involved being the lungs (49%), bones (40%), liver (19%), soft tissue (9%), distant lymph nodes (8%), brain (7%), kidney (2%), orbit (2%), and pancreas (2%). When viewed histologically, the types of tumors that experience distant metastases are salivary duct carcinoma (53%), adenocarcinoma (42%), high-grade carcinoma (23%), expleomorphic adenoma carcinoma (20%), acinic cell carcinoma (16%), adenoid cystic carcinoma (14%), mucoepidermoid carcinoma (7%), and myoepithelial carcinoma (6%)<sup>1</sup>.

Psarris et al. (2020) presented a case of distant metastatic by high-grade parotid adenocarcinoma to the uterus and lungs, 4 years after the patient underwent resection of the right parotid gland and chemoradiation<sup>6</sup>. Research by Negishi et al. (2022) presented a case of distant metastases by parotid gland adenocarcinoma involving the lungs. In that case the patient

## Parotid Gland Adenocarcinoma: A Case Report

had a total resection of the right parotid gland and then continued with chemoradiation therapy. 14 months later, a nodule was found in the patient's right lung<sup>5</sup>. Additionally, research by Smith et al. (2020) presented parotid gland metastatic adenocarcinoma to the breast. The patient underwent left radical parathyroidectomy and underwent radiotherapy. 3 months later the patient complained of a lump in the left breast superolateral quadrant, which was painless and had no discharge or skin retraction<sup>7</sup>.

Meanwhile, the patient in this case was known to have experienced recurrence in the right parotid gland 2 times and distant metastases to the left breast. The patient is known to have received chemotherapy injections 6 times in 2014 and radiotherapy 35 times in 2016. In 2021, the patient started receiving oral chemotherapy treatment (Exemestane).

The rarity of these cases results in the absence of standardized systemic therapy for salivary gland cancer. Treatment options for metastatic parotid adenocarcinoma are largely based on clinical experience and retrospective studies. Surgical resection of the parotid gland with metastasectomy followed by adjuvant radiotherapy is the current treatment strategy. Treatment with chemotherapy alone is still controversial because it does not offer significant benefits. However, the literature has shown that chemoradiotherapy regimens can increase the efficacy of radiotherapy through radiosensitization while providing adjuvant systemic therapy against distant metastases<sup>7</sup>. In a recent case report, the use of Nivolumab proved effective in cases of parotid adenocarcinoma that experienced recurrence and distant metastases, and had been treated with Cisplatin<sup>5</sup>.

The low incidence means that the reported epidemiological knowledge of malignant neoplasms of the parotid gland is low. Although rare, this disease is still a serious health problem in the general population because of its poor prognosis and potential for distant metastases. Long-term follow-up and high clinical suspicion are indispensable for the early diagnosis of metastatic salivary gland cancer. Through early detection and treatment, local or systemic tumor recurrence can be prevented. Further studies are needed to assess the impact of early detection of parotid metastases on tumor survival and recurrence<sup>7</sup>.

## CONCLUSION

Adenocarcinoma no otherwise specified (NOS) and polymorphous adenocarcinoma (PAC) are malignant tumors that can occur in the parotid gland. Although rare, recurrence and distant metastases can occur in both types of malignant tumors. This disease is a serious health problem because it has a poor prognosis. Currently, there is no standardization of systemic therapy in cases of recurrence and metastases because the reported cases are relatively small. Therefore, further research regarding parotid adenocarcinoma that has recurrence and distant metastases is urgently needed.

## REFERENCES

- I. Ali, S., Bryant, R., Palmer, F. L., DiLorenzo, M., Shah, J. P., Patel, S. G., dan Ganly, I. 2015. Distant Metastases in Patients with Carcinoma of the Major Salivary Glands. *Annals of Surgical Oncology*. 22(12): 4014-4019.
- II. Alvi, S., Chudek, D., dan Limaiem, F. 2022. Parotid Cancer. *StatPearls: FL*.
- III. Khosla, D., Verma, S., Gupta, N., Punia, R., Kaur, G., Pandey, A., dan Dimri, K. 2017. Polymorphous Low Grade Adenocarcinoma of the Parotid in a Teenager. *Iranian Journal of Otorhinolaryngology*. 29(94): 299-302.
- IV. Mimica, X., Katabi, N., McGill, M. R., Hay, A., Zaroni, D. K., Shah, J. P., dkk. 2020. Polymorphous Adenocarcinoma of Salivary Glands. *Oral Oncology*. 95: 52-58.
- V. Negishi, Y., Okamoto, I., Ueda, Y., Sato, H., Tanigawa, M., Nagao, T., dan Tsukahara, K. 2022. Complete Response to Nivolumab of Resected Adenocarcinoma NOS With Parotid Gland Origin and Lung Metastasis. *In Vivo*. 36: 2840-2843.
- VI. Psarris, A., Koufopoulos, N., Grivas, A., Papatheodorou, D. C., Khaldi, L. 2020. Tumor to Tumor Metastasis from Adenocarcinoma Not Otherwise Specified of the Parotid Gland to Uterine Leiomyoma: Presentation of a Unique Case. *Cureus*. 12(1): e6789.
- VII. Smith, B. M., Azouz, V., Liu, L., dan Williams, G. 2020. Parotid Adenocarcinoma Metastasis to the Breast: A Case Report. *Journal of Surgical Case Reports*. 2020(6): 1-3.
- VIII. Speight, P. M. dan Barrett, A. W. 2020. Salivary Gland Tumours: Diagnostic Challenges and An Update on the Latest WHO Classification. *Diagnostic Histopathology*. 26(4): 147-158.
- IX. Young, A. dan Okuyemi O. T. 2022. Malignant Salivary Gland Tumors. *StatPearls: FL*.