

Hepatoprotective Effect of Roselle (*Hibiscus sabdariffa* L.) in *N*-Diethylnitrosamine Induced Liver Damage in Rats

Adam O. Abaker^{1*}, Abdelkareem A. Ahmed², Eman I. Kandil³, Eman N. Aly⁴, Saber Y. Adam⁵

¹Food and Nutrition Research Centre, University of Al Fashir, North Darfur State-Sudan

²Department of Veterinary Sciences, Faculty of Animal and Veterinary Sciences, Botswana University of Agriculture and Natural Resources, Gaborone, Botswana.

³Department of Biochemistry, Faculty of Science, Ain Shams University, Cairo-Egypt

⁴National Center for Radiation Research and Technology, Atomic Energy Authority, Cairo-Egypt

⁵Animal Welfare Center, Nyala, Sudan; Medical and Cancer Research Institute, Nyala, Sudan

ABSTRACT

Introduction: Liver damage due *N*-diethylnitrosamine (DEN) is a global health challenge. The aim of this study was to assess the efficacy of roselle (*Hibiscus sabdariffa* L.) calyces' water-extract as a Hepatoprotective material against liver damage induced by DEN in rats.

Material and methods: Twenty-five (25) adult female albino Wistar rats were grouped randomly into five groups (Gs): G1, Normal healthy animals (act as control); G2, DEN; G3, Roselle extract; G4, DEN + roselle-extract; G5, DEN + nanoselenium. Tissue malondialdehyde (MDA) as oxidative stress marker, and antioxidant enzymes, superoxide dismutase (SOD) and catalase (CAT) were measured. Also, caspase-3 as apoptotic marker and tumor necrosis factor-alpha (TNF- α) as inflammatory factor, were assessed.

Results: The results revealed decrease in MAD level and significant increase in antioxidant markers, SOD and CAT in DEN-group compared with control group. Moreover high increase in apoptotic marker, caspase-3; and significant decrease in TNF- α in DEN-group were recorded compared with normal control. Administration of roselle-extract led to significant increase in MDA and decrease in SOD and CAT parameters. In addition, high decrease in caspase-3 and increase in TNF- α was noticed. These findings were ensured by histopathological results.

Conclusion: The roselle-extract improve liver architecture, and might be involved in the hepatoprotective activity against DEN exposure. Further studies are needed for elucidation clinical applications of the plant bioactive materials and explore its mode of action in attenuating and preventing carcinogenesis.

KEYWORDS: Antioxidants; Diethylnitrosamine; Hepatoprotective; *Hibiscus sabdariffa*; Liver; Rats.

ARTICLE DETAILS

Published On:
06 March 2023

Available on:
<https://ijmscr.org/>

ADDREVIATIONS:

b.w. = body weight; CAT = catalase; DEN = *N*-Diethylnitrosamine; DMSO = dimethyl-sulfoxide; HCC = Hepatocellular carcinoma; IARC=; i. p. = intraperitoneal; MDA = Malondialdehyde; NCI = National Cancer Institute; PBS = phosphate-buffered saline; SOD = superoxide dismutase; TAA = Thiacetamide; TNF- α = Tumor necrosis factor-alpha.

INTRODUCTION

Liver plays a pivotal role in regulating various physiological processes in the body such as metabolism, secretion and storage. Human beings may expose to various injurious compounds and toxic metabolic byproducts through environmental exposure, consumption of contaminated food or during exposure to occupational environmental chemical substances [1]. Liver has great capacity to detoxify toxic substances and synthesize useful principles. Therefore, damage on the liver inflicted by hepatotoxic agents is of grave

Hepatoprotective Effect of Roselle (*Hibiscus sabdariffa* L.) in *N*-Diethylnitrosamine Induced Liver Damage in Rats

consequences [2]. Liver diseases are still a global health problem and may be classified as acute or chronic hepatitis (inflammatory liver diseases), hepatosis (non-inflammatory diseases) and cirrhosis (degenerative disorder resulting in liver fibrosis). A recent International Agency for Research on Cancer (IARC) study on the role of alcohol consumption suggested that 17% of all liver cancer cases diagnosed in 2020 could have been avoided by reducing alcohol consumption. Tobacco smoking is also an important cause of liver cancer [3]. Liver cancer is the third most common cause of cancer death globally, and it is among the five most common causes of cancer death in 90 countries across the world. However, there is an indication that most cases of liver cancer could be prevented [4]. Hepatocellular carcinoma (HCC) is a primary malignancy of the liver and one of the most common cancer worldwide [5].

N-Diethylnitrosamine (DEN) is frequently used to induce hepatocarcinogenesis in cirrhotic experimental animals [6], possibly by causing oxidative stress and cellular injury with enhanced formation of detrimental free radicals. DEN is a well-known potent hepatocarcinogenic agent present in tobacco smoke, water, cured some fried meal, cheddar cheese, agricultural chemicals, cosmetics, and pharmaceutical products [7-9]. DEN metabolizes to its active ethyl radical, which can interact with DNA causing mutation and subsequent carcinogenesis [10, 11]. Wang, *et al.*, [12] reported that the administration of DEN alone is not recommended for HCC rat model. There are several drugs available to induce primary HCC in rats. Ethanol, carbon tetrachloride (CCl₄), aflatoxin, nitrosamines, amino-azo dyes, aromatic amine and so on all are used to induce HCC in animal models [12].

Plants have long been used as a source of food and medicine. They not only serve as vegetables of high nutritive value, but their different parts (leaf, fruit, and root) are used for health remedial purposes [13]. As a result of accumulated experience from the past generations, today, all the world's cultures have an extensive knowledge of herbal medicine. Two thirds of the new chemicals identified yearly were extracted from higher plants [14]. Roselle (Malvaceae, Karkedeh in Arabic) *Hibiscus sabdariffa* L., is an attractive plant believed to be native to Africa, is cultivated in both Sudan and Eastern Taiwan [15]. Typically, the calyces of the plant are used in the manufacturing of beverages, jam, and vegetable gelatin [16]. However, *H. sabdariffa* L. has many other applications in Africa, it also used as an herbal medicine to treat hypertension, cholesterol production, and cancer progression [15, 17, 18]. Phenolic compounds comprising anthocyanins, the most-abundant dye in hibiscus have strong antioxidant property [17, 19]. In the present study, *Hibiscus sabdariffa* calyces-extract was examined as active chemo-protective material against hepatocellular carcinoma induced by DEN in rat liver tissues.

MATERIAL AND METHODS

Chemicals:

All chemicals used in this study were of analytical grade. *N*-diethylnitrosamine (DEN) was purchased from Sigma, Germany; Thiacetamide (TAA) by Al-Gumhoria chemical Company, Egypt. All assay kits were purchased by Bio-Diagnostic, Egypt; Bio-system, Spain; or AssayPro, USA.

Plant calyces:

Roselle (*Hibiscus sabdariffa* L.) dried calyces were purchased by local distributor in downtown, Attaba-Cairo, Egypt. Extraction was carried out according to Builders, *et al.*, [20] with some modification comprised the temperature and duration of extraction according to Abaker, *et al.*, [6].

Animals:

Twenty-five healthy female Swiss Albino rats of six weeks' age, weighing 110 -130g were used for this study. The animals were purchased from the breeding unit of National Cancer Institute (NCI), Cairo-Egypt. The animals were housed 5 per cage in normal environmental and nutritional condition, fed by standard cubic foods and water *ad libitum*.

Experimental design:

Hepatic injury was induced in rats by intraperitoneal (i.p.) injection of 45 mg/Kg b.w. *N*-diethylnitrosamine (DEN) once/month for 5 months' after initial activation by Thiacetamide (TAA) i.p. injection of 50 mg/Kg b.w. twice per month for 4 months according to Klaunig *et al.*, [21]. DEN and TAA were dissolved by normal saline to the selected concentration of final 0.5 ml volume. Treatments by roselle-calyx extract were by oral gavage administrated of 250 mg/Kg b.w triple doses/week for 16 weeks. Nanoselenium was induced in rats by i.p. injection of 2 mg/Kg b.w. dissolved in dimethyl-sulfoxide (DMSO). After one-week acclimatization the experimental rats were classified randomly into five groups (n = 5): The rats of group 1 (NC): This group served as normal healthy control. Group 2 (DEN): This group serve as DEN-induced group. Group 3 (Rx): Serve as drug-only (roselle-extract) group. Group 4 (DEN+Rx): Were administrated DEN and TAA as in Group 2 in addition to Roselle extract (Rx), and serve as therapeutic group. Group 5 rats (DEN+nSe): Were administrated DEN and TAA as in Group 2 in addition to nanoselenium (nSe), this group serves as standard therapeutic group for comparison, because nSe is a potent hepatoprotective agent and present as seleno-protein (natural antioxidant) according to Zhang, *et al.*, [22].

Sampling and analysis of biochemical parameters:

All the experimental animals were withheld diet for 24 h before sampling and anesthetizing by diethyl ether (Sigma-Aldrich Chem. Ltd.) then scarified by cervical dislocation. The rat-livers were excise and placed in 10% formalin for histological investigations, whereas the rest of the livers were homogenized with phosphate-buffered saline (PBS) to prepare 10% liver homogenate and lysate.

Hepatoprotective Effect of Roselle (*Hibiscus sabdariffa* L.) in *N*-Diethylnitrosamine Induced Liver Damage in Rats

Evaluation of antioxidant status:

The liver homogenate centrifuged at 10,000 rpm for 10 min in a refrigerated centrifuge (4 °C) the supernatant was used for antioxidant assay, superoxide dismutase (SOD) according to Minami and Yoshikara, [23], catalase (CAT) according to Sinha, [24], malondialdehyde (MDA) according to Yoshida, *et al.*, [23].

Histopathological examination:

The specimens of the animals- livers that fixed in 10% buffered neutral formalin solution were dehydrated in covenantal ethanol gradient, cleared in xylene then infiltrated with wax. The cleared tissues were embedded in paraffin and five microns' thick section were prepared and stained by hematoxylin-eosin (H and E) according to Banchroft, *et al.*, [25]. Assessment of necrosis, fibrosis, fatty infiltration was examined under microscope and photographed.

Statistical analysis:

The results were expressed as mean ± SD. Statistical significance among more than two groups was tested using

one-way ANOVA by SPSS computer program, version 20. Differences among groups were considered to be statistically significant at $p < 0.05$ and highly significant at $p < 0.001$.

RESULTS

Oxidative stress parameter and antioxidant enzymes:

Lipid peroxidation of liver homogenate was expressed as malondialdehyde (MDA). This parameter represents oxidative stress due to intoxication of the animal livers by diethylnitrosamine (DEN). Administration of roselle extract (Rx), induced significant decrease ($p < 0.001$) in the content of MDA and significant increase in antioxidant enzymes, SOD and CAT levels compared with the DEN-group. Also, induction of nanoselenium (nSe) (standard drug) revealed better results than DEN+Rx group compared with DEN - group. However, administration of Rx alone revealed no significant change compared with control (table 1).

Table (1): Effect of Roselle extract (Rx) and nanoselenium (nSe) on liver tissue-antioxidants', malondialdehyde (MDA), superoxide dismutase (SOD) and catalase (CAT) levels.

Parameters Groups	MDA(µM/L) Mean ± S.D	SOD (µg/ml) Mean ± S.D	CAT (µmol/ml) Mean ± S.D
G1 Control	29.33±06.32 ^b	4.05±0.11 ^b	41.05±1.15 ^b
G2 DEN	105.00±05.41 ^a	1.50±0.29 ^a	24.21±1.09 ^a
G3 Roselle extract (Rx)	27.83±03.79 ^b	3.97±0.19 ^b	41.85±0.74 ^b
G4 DEN+Rx	69.00±12.35 ^{ab}	2.14±0.12 ^{ab}	32.54±3.97 ^{ab}
G5 DEN+nSe	71.50±21.43 ^{ab}	2.95±0.40 ^{ab}	34.23±2.79 ^{ab}

A probability, $p < 0.05$; A indicates significance vs normal control group, b vs DEN.

Tumor marker parameters

Table (2) showed the effect of Rx administration as significant increase ($p < 0.001$) in the level of caspase-3 the apoptotic marker, compared with DEN-group. It is obvious that administration of Rx alone revealed significant change compared to control group. Despite there is no significant difference in the level of caspase-3 between DEN+Rx and

DEN+nSe groups as treatment drugs, the level of the enzyme in the former group is better. On the other hand the table revealed highly elevation in the level of TNF- α compared with the control group. Administration of Rx and nSe revealed significant decrease in the content of this parameter compared with DEN-group.

Table (2): Effect of Roselle extract (Rx) and nanoselenium (nSe) on liver tissue-caspase-3 and TNF- α .

Parameters Groups	Caspase-3 (U/ml) Mean ± S.D	TNF- α (U/L) Mean ± S.D
G1 Control	256.90±20.71 ^b	06.65±0.80 ^b
G2 DEN	171.82±2.63 ^a	16.64±3.54 ^a
G3 Roselle extract (Rx)	341.82±5.56 ^{ab}	06.97±0.56 ^b
G4 DEN+Rx	203.53±10.22 ^{ab}	10.07±3.14 ^b
G5 DEN+nSe	195.00±3.13 ^{ab}	08.77±2.27 ^b

A probability, $p < 0.05$; a indicates significance vs normal control group, b vs DEN

Histopathology

Images of the liver sections of normal control and Rx group showed no histopathological changes, whereas DEN - group showed histopathological alterations, comprised dysplastic

nodules of hepatocyte surrounded by fibrosis connective tissues. Administration of Rx and nSe led to improve in the hepatic architecture compared with the picture of DEN-group.

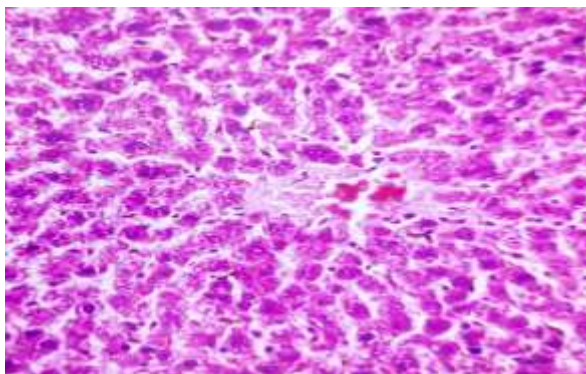


Fig. 1: G1, Normal control section of rat liver, showing normal histological feature of hepatic tissue. (H and E X400).

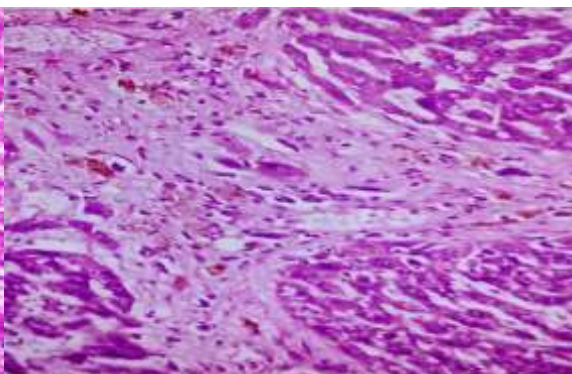


Fig. 2: G2, Hepatic tissue section of positive control (DEN) showing dysplastic nodules surrounded by fibrotic connective tissue, loss of cellular boundaries.

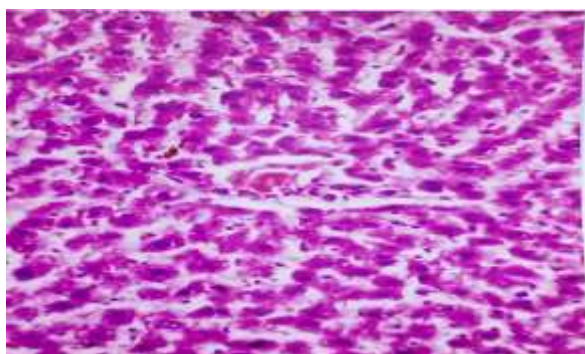


Fig. 3: G3, Liver section of rats administrated roselle-extract showing no histological alteration. (H and E X400).

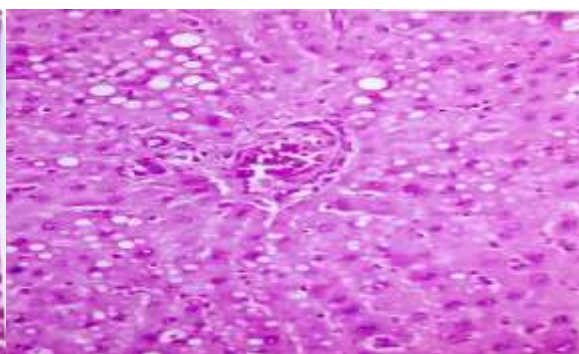


Fig. 4: G4, liver section of DEN-induced animals treated by roselle-extract showing fatty degeneration of hepatocytes. (H and E X400).

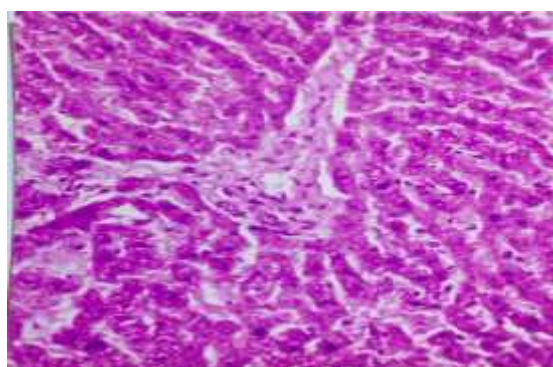


Fig. 5: G5, DEN induced animals treated by nanoselenium, showing no histopathological changes. (H and E X400).

DISCUSSION

Cancer is still regarded a global life-threatening disease. Hepatocellular carcinoma (HCC) as primary liver carcinoma is considered as the sixth most common malignancy all over the world [26]. In these regards, great efforts have been made to attenuate the intoxication of hepatic cells (hepatoma) by diethylnitrosamine (DEN) using natural products. Wang, *et al.*, [12] emphasized that the age of the rats might be an important factor in the development of a successful HCC model. They found that five-week-old rats were better than eight-week-old rats, where the liver function of eight-week-old rats may be more perfect and mature than the five-week-

old rats; hence, the former group could metabolize the drugs better than the latter group. Thus, DEN could not injure the liver easily in the eight-week-old rats. The second approach of Wang, *et al.*, [12] combine DEN with other drugs. In the present study, we utilized rats aged six-weeks, and initiate the cirrhosis by thiacetamide (TAA). Plants and plant extracts were already used for treating or preventing cancer progression [27, 28]. Among the natural-cellular antioxidants, SOD and CAT have received vast studies. Superoxide dismutase catalyzes the dismutation of superoxide anion to H_2O_2 and O_2 . Because accumulation H_2O_2 is still harmful to cells, catalase and glutathione

Hepatoprotective Effect of Roselle (*Hibiscus sabdariffa* L.) in N-Diethylnitrosamine Induced Liver Damage in Rats

peroxidase (GPx) further catalyze the decomposition of H₂O₂ to water and molecular oxygen (O₂). Plants contain natural antioxidants that possess beneficial effects in health maintenance, management of diseases, and alleviating the harmful effects of toxic agents [29]. Phenolic compounds are a class of antioxidant agents that can inhibit and scavenge free radicals due to their redox properties [30]. Nutri-medicinal plants include herbaceous plants, in addition to roots, bark, leaves, flowers, and seeds. The calyces of Hibiscus (Karkedeh) flowers are used for preparing hot (sour tea) and cold beverages that are consumed all over the world. Due to their perceived potential health benefits, commercial preparations of *H. sabdariffa* extracts (HSE) are currently marketed as supplements and these extracts have gained an important position in some markets [31, 32]. In the present study the water extract of *H. sabdariffa* (Karkedeh) was used to treat HCC that induced by intraperitoneal (i.p.) injection of DEN in female Wister-albino experimental rats. The hepatic cells damage was assessed by increase in the level of MDA (as lipid peroxidation) and decrease in SOD and CAT activities, as antioxidants. Oral administration of 250 mg/Kg body weight of roselle extract significantly restored the levels of SOD and CAT (group 4) when compared with DEN-induced group, these results agree with the findings of Srivastava and Shivanandappa [33]; Gite, *et al.*, [34] despite the difference of the plants used for free radical scavenging, but they share the property of their consumption for promoting liver health. Caspase-3 beside other caspases such as caspase-9 induce apoptosis [32]. Intoxication lead to decrease in the level of caspase-3, whereas administration of roselle extract lead to notable elevation of the level of the enzyme compared to the positive control. Selenium is a micronutrient that had been suggested to reduce the risk of cancer in the present study, nanoselenium is used as standard drug for comparison with roselle-extract. The finding of this study is in harmony with Cheng, *et al.*, [35] who noted that in recent decades, increasing studies have investigated the potential role of selenium in liver cancer involving several major cancer-associated signaling pathways, metabolic pathways, and antioxidant defense systems both *in vitro* and in preclinical models. Cheng, *et al.*, [35] was also observed that there was an increase in the trend of development of novel selenium nanoparticles and selenium-containing inhibitors aiming to improve the therapeutic efficacy and relative potency of selenium. This finding is in consistent with the present study, where nSe showed significant potential in restoring the level of antioxidants and anti-apoptotic potential. The histopathological investigations were performed to give direct evidence of the possibility of the roselle extract to minimize disruption of hepatocytes architecture and accelerate hepatic regeneration.

CONCLUSION

In conclusion, karkedeh (roselle)-extract containing phenolic compounds mainly anthocyanins down regulate free radicals'

elevation, and improve liver architecture. Activity of the extract might be involved in the hepatoprotective activity against DEN exposure. Further studies are needed for roselle clinical application and explore its mode of action in attenuating and prevention of carcinogenesis.

ACKNOWLEDGMENTS

Part of this work was done in the National Center for Radiation Research and Technology, Atomic Energy Authority, Cairo-Egypt. The authors wish to thank the director of the center for his permission and interest in this study. The corresponding author is gratefully acknowledged for individual research funding as grant.

REFERENCES

- I. Chatterjee, S. Datta, R. Dey, A., Pradhan, P., and Acharya, K. (2012). In vivo Hepatoprotective activity of Ethanolic extract of *Russula albonigra* against Carbon Tetrachloride-induced Hepatotoxicity in Mice. *Research J. Pharm. And Tech.* 5 (8): 1034-1038
- II. Shanmugasundaram, P. and S. Venkataraman. (2006). Hepatoprotective and antioxidant effects of *Hygrophila auriculata* (K. Schum) Heine Acanthaceae root extract. *Journal of Ethnopharmacology*,. 104(1): p. 124-128.
- III. Rungay, H., Shield, K., Charvat, H., Ferrari, P., Sornpaisarn, B., Obot, I., et al. (2021). Global burden of cancer in 2020 attributable to alcohol consumption: a population-based study. *Lancet Oncol*, 22(8):1071–80. [https://doi.org/10.1016/S1470-2045\(21\)00279-5](https://doi.org/10.1016/S1470-2045(21)00279-5)
- IV. Rungay, H., Arnold, M., Ferlay, J., Lesi, O., Cabasag, C. J., Vignat, J., et al. (2022). Global burden of primary liver cancer in 2020 and predictions to 2040. *J Hepatol.*, Published online 6 October 2022; <https://doi.org/10.1016/j.jhep.2022.08.021>
- V. Plymoth, I., Chemin, P., Boffetta, P., and Hainaut, P. (2009). Hepatocellular carcinoma-a worldwide translational approach. *Cancer Lett.*, 286:3-4.
- VI. Abaker, A. O., Aly, E. N., Kandil, E. I. and Shalaby, K. F. (2015). Chemopreventive effect of *Hibiscus sabdariffa* calyx anthocyanins and Nano-selenium against N-diethylnitrosamine induced hepatocellular carcinoma in rats. *Egy. J. Pure and App. Sci.* 53 (3): 23 – 33.
- VII. Sullivan, B. P., Meyer, T. J., Stershic, M. T. and Keefer, L. K. (1991). Acceleration of N-nitrosation reactions by electrophiles. *IARC Sci. Pub.* 1: 370-374.
- VIII. Reh, B. D. and Fajen, J. M. (1996). Worker exposures to nitrosamines in a rubber vehicle sealing plant. *Am. Ind. Hyg. Assoc. J.* 57: 918-923.

Hepatoprotective Effect of Roselle (*Hibiscus sabdariffa* L.) in *N*-Diethylnitrosamine Induced Liver Damage in Rats

- IX. Brown, J. L. (1999). *N*-Nitrosamines. *Occup. Med.* 14: 839-848.
- X. Anis, K. V., Rajesh-Kumar, N. V., and Kuttan, R. (2001). Inhibition of chemical carcinogenesis by biberine in rats and mice. *J. Pharm. Pharmacol.* 53: 763-768.
- XI. Chakraborty, T., Chatterjee, A., Rana, A., Dhachinamoorthi, D., Kumar, P. A., and Chatterjee, M. (2007). Carcinogen induced early molecular events and its implication in the initiation of chemical hepatocarcinogenesis in rats: chemopreventive role of vanadium on this process. *Biochim Biophys Acta* 1772:48–59.
- XII. Wang, F., Qu, W., Li, Y., Liu, H., Li, B., Qi, J., Qin, C. (2016). Diethyl nitrosamine alone was not recommended for primary hepatocellular carcinoma model in rats. *Int. J. Clin. Exp. Pathol.* 9 (10):10346 -10350.
- XIII. Abifarin, T. O., Afolayan, A. J., and Otunola, G. A. (2019). Phytochemical and Antioxidant Activities of *Cucumis africanus* L.f.: A Wild Vegetable of South Africa. *J. Evidence-Based Integr. Med.* 24: 1- 8.
- XIV. Al Snafi, A. E. (2016). Medicinal plants with antioxidant and free radical scavenging effects (part 2): plant based review. *IOSR J. of Pharm.*, 6(7): 62 – 82.
- XV. Müller, B. M. and Franz, G. (1992). Chemical structure and biological activity of polysaccharides from *Hibiscus sabdariffa*. *Planta Med.*, 58 :60–67. [Google Scholar] [CrossRef] [PubMed]
- XVI. Mohamed, R., Fernandez, J., Pineda, M., and Aguilar, M. (2007). Roselle (*Hibiscus sabdariffa*) seed oil is a rich source of gamma-tocopherol. *J. Food Sci.* 72 :S207–S211. [Google Scholar] [CrossRef] [PubMed]
- XVII. Ologundudu, A., Ologundudu, A. O., Oluba, O. M., Omotuyi, I/ O., and Obi, F. O. (2010). Effect of *Hibiscus sabdariffa* anthocyanins on 2, 4-dinitrophenylhydrazine-induced tissue damage in rabbits. *J. Toxicol. Envir. Health Sci.* 2(1): 1 – 6.
- XVIII. Da-Costa-Rocha I, Bonnlaender B, Sievers H, Pischel I, Heinrich M. (2014). *Hibiscus sabdariffa* L.-a phytochemical and pharmacological review. *Food Chem.* 165:424-443.
- XIX. Abdel-Ghaffer, F. R. (2013) attenuation of CCl₄-induced hepatic antioxidant disorder and oxidative stress by *hibiscus rosasinensis* extract in albino rats. *Int. J. Med. Plant Altern. Med.* 1(1): 1 – 12.
- XX. Builders, P. F., chukuemeka, R. E., Florence, D. T. and Builders, M. I. (2010) assessment of intrinsic properties of the freeze-dried and formulated extract of *Hibiscus sabdariffa* Linn. (Malvaceae). *Afric. J. Pharmacy and Pharmacog.* 4(6): 304 – 313.
- XXI. Klaunig, J. E., Pereira, M. A., Ruch, R. J. and Weghorst, C. M. (1988). Dose-response relationship of diethylnitrosamine-initiated tumors in neonatal balb/c mice: effect of phenobarbital promotion. *Toxicol. Pathol.* 16(3): 385 – 391.
- XXII. Zhang, Z., Bi, M., Liu, Q., Yang, J., and Xu, S. (2016). Meta-analysis of the correlation between selenium and incidence of hepatocellular carcinoma. *Oncotarget*, 47: 77110-77116.
- XXIII. Minami, M and Yoshikara, H. (1979). A simplified assay method of superoxide dismutase activity for clinical use. *Clin. Chim. Acta.* 92: 337 – 342
- XXIV. Sinha, A. K. (1972). Colorimetric assay of catalase. *Anal. Biochem.* 47: 389.
- XXV. Bancroft, J. D., Stevens, A. and Turner, D., R. (1996). Theory and practice of histological techniques. Fourth ed. New York.
- XXVI. Former, A., Reig, M. and Bruix, J. (2018). Hepatocellular carcinoma. *Lancet.* 391: 1301–1314.
- XXVII. Cai, Y. Z., Sun, M., Xing, J., Luo, Q., and Corke, H. (2006). Structure-radical scavenging activity relationships of phenolic compounds from traditional Chinese medicinal plants. *Life Sciences.* 78: 2872–2888.
- XXVIII. Ochwang, I. DO., Kimwele, C. N., Oduma, J. A., Gathumbi, P. K., Mbaria, J. M., and Kiama, S. G. (2014). Medicinal plants used in treatment and management of cancer in Kakamega County Kenya. *J. Ethnopharmacol.* 151:1040–1055.
- XXIX. Mishra, K., Ojha, H. and Chaudhury, N. K. (2012). Estimation of antiradical properties of antioxidants using DPPH assay: a critical review and results. *Food Chem.* 130: 1036-1043.
- XXX. Jimoh, F. O., Adedapo, A. A., and Afolayan, A. J. (2011). Comparison of the nutritive value, antioxidant and antibacterial activities of *Sonchus asper* and *Sonchus oleraceus*. *Rec. Nat. Prod.* 2: 29-42.
- XXXI. Lin, H. H., Chen, J. H., Kuo, W. H., Wang, C. J. (2007). Chemopreventive properties of *Hibiscus sabdariffa* L. on human gastric carcinoma cells through apoptosis induction and JNK/p38 MAPK signaling activation. *Chem. Biol. Interact.*, 165: 59–75.
- XXXII. Chiu, C-T., Chen, J-H., Chou, F-P. and Lin, H-H. (2015). *Hibiscus sabdariffa* Leaf Extract Inhibits Human Prostate Cancer Cell Invasion via Down-Regulation of Akt/NF-κB/MMP-9 Pathway, *Nutrients*, 7(7): 5065-5087.
- XXXIII. Srivastava, A and Shivanandappa, T. (2010). Hepatoprotective effect of the root extract of *Decalepis hamiltonii* against carbon tetrachloride-induced oxidative stress in rats. *Food Chem.* 118: 411–417.
- XXXIV. Gite, S., Yadav, S., Nilegaonkar, S., and Agte, V. (2014). Evaluation of hepatoprotective potential of functional food formulations using in vitro and in

Hepatoprotective Effect of Roselle (*Hibiscus sabdariffa* L.) in *N*-Diethylnitrosamine Induced Liver Damage in Rats

vivo models of CCl₄ radical induced toxicity. *Intr. J. Interdisciplinary and Multidisciplinary Studies*. 1(10): 6 – 13.

- XXXV. Cheng, C-S., Wang, N. and Feng, Y. (2019). Selenium in the Prevention and Treatment of Hepatocellular Carcinoma: From Biomedical Investigation to Clinical Application. *Toxicology Reports*, 4, (2017): 455-462