

Gestational Trophoblastic Disease Metastasized to the Vagina: Case Report

Radhiah Karim Sanrang¹, Irma Savitri CH. Rasjad², Syahrul Rauf³

^{1,2,3}Department of Obstetrics and Gynecology, Faculty of Medicine, Universitas Hasanuddin, Makassar, South Sulawesi, Indonesia

ABSTRACT

Background: Gestational trophoblastic disease is caused by placenta abnormalities and can metastasize in several places outside the uterus, including the vagina. Its criteria are based on physical examination, laboratory examination, ultrasonography, and histopathology. In addition, the malignancy classification is based on FIGO 2000. Treatment is then carried out according to the malignancy level, and monitoring of results can be carried out based on the β -hCG measurement.

Case illustration: A 38-year-old multiparous patient with a gestational age of 12 weeks based on HPHT experienced bleeding in the last three hours before admission to the hospital, originating from a 4 x 4 cm vaginal mass detected in the lower 1/3 of the vagina and active bleeding. Ultrasound examination of the whole abdomen showed that the uterus was enlarged and anteflexed with a uterine size of 18x20 cm according to the gestational age of 20 weeks; a multilocular cystic mass appeared in the adnexa area with the impression of a lutein cyst measuring 3x3 cm; a heterogeneous mass appeared in the uterine cavity with multiple anechoic areas giving a Honeycomb appearance; no gestational sac was seen, and the myometrium was intact. Also, the examination of β -HCG levels was found to be more than 1,000,000 mIU/mL. Based on the presence of a vaginal mass suspected of being metastatic from the uterus, a WHO scoring was performed, and a score of 7 was obtained so that it was included in the high-risk category.

Conclusion: Diagnosis and classification of gestational trophoblastic disease help determine appropriate management, thereby increasing patient treatment success.

KEYWORDS: Gestational, malignancy, trophoblast.

ARTICLE DETAILS

Published On:
21 December 2022

Available on:
<https://ijmscr.org/>

INTRODUCTION

A gestational trophoblastic disease is a group of uncommon conditions associated with pregnancy. This disease arises from the abnormal placenta and ranges from pre-cancerous to malignancy.¹

Gestational trophoblastic disease results from the proliferation of placental trophoblast cells. Initially, abnormal fertilization occurs, resulting in proliferative trophoblast tissue and swelling of the vesicular placental villi. This change causes a change in shape to become like a grape, caused by the fertilization of an empty egg by one or two duplicated haploid sperm (46, XX). Most are also caused by fertilization of a normal egg by two sperm and result in a triploid karyotype (69, XXY).²

Moreover, the gestational trophoblastic disease has the potential to invade the uterus and metastasize via the hematogenous route, and the organs most commonly affected are the lungs, vagina, vulva, kidneys, and brain. If the

monitoring reveals a lesion in the vagina or an X-Ray examination shows a metastatic picture, the patient is included in the category of gestational trophoblastic disease.³ Although the gestational trophoblastic disease is very aggressive, it responds very well to an appropriately administered chemotherapy regimen.⁴

CASE ILLUSTRATION

A 38-year-old woman, Gravida 4, with a gestational age of 12 weeks and six days, came to the Hasanuddin University Hospital Makassar on January 26, 2021, at 20.30 WITA. Her last menstruation was on October 28, 2020; she came with the complaint of bleeding from the birth canal since 18.30 WITA (two hours since the bleeding started). The patient had a history of the same complaint a few days ago, but the bleeding stopped. The patient also had a history of nausea, vomiting, difficulty eating, and difficulty drinking for the past few days. The patient had no history of hypertension, diabetes mellitus,

Gestational Trophoblastic Disease Metastasized to the Vagina: Case Report

asthma, and drug allergies. During her pregnancy, the patient made two antenatal visits, namely at the Puskesmas [Community Health Center] and the Obstetrics and Gynecology Specialist Clinic.

General examination showed that the patient was conscious, with a blood pressure of 100/70 mmHg, a pulse of 80 times/minute, breathing 18 times/minute, and a temperature of 36.8°C. The external examination uncovered

that the uterine fundus height was one finger below the center, having flux in the form of blood and smooth urination and defecation. Furthermore, vaginal examination revealed no abnormalities in the vulva; vaginal mass appeared in the lateral area measuring 4 x 4 cm, detected in the lower 1/3 of the vagina, with a cystic consistency and immobile, and active bleeding appeared from the mass; smooth portfolio; uterus AD/CD with no abnormalities; the release of blood.

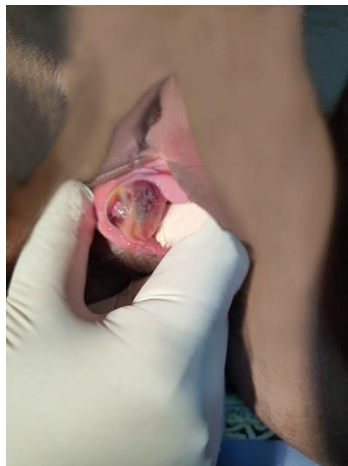


Figure 1. Mass is seen in the lower 1/3 of the vagina.

Laboratory examination was carried out on January 27, 2021, with the results of a hemoglobin level of 6.4 g/dl; total leukocyte counts of 11.710/uL; platelets of 209.00/uL; hematocrit of 18.4%; prothrombin time (PT) of 16.3; activated partial thromboplastin time (APTT) pf 31.3; creatinine of 0.8 mg/dl; blood sugar at 160 mg/dl; Glutamate Pyruvate Transaminase of 145 u/L; thyroid hormone (fT4) of > 100; thyroid-stimulating hormone (TSHs) of 0.015. Then, the β -HCG examination was carried out on January 19, 2021, resulting in more than 1,000,000 mIU/mL. Investigations obtained chest x-ray results within normal limits. In addition,

an ultrasound examination of the whole abdomen showed that the uterus was enlarged and anteflexed with a uterine size of 18x20 cm according to the gestational age of 20 weeks; a multilocular cystic mass appeared in the adnexal area with the impression of a lutein cyst; a heterogeneous mass appeared in the uterine cavity with multiple anechoic areas, giving a Honeycomb appearance; no gestational sac was seen, and intact myometrium was indicative of a hydatidiform mole. The examination result was a hydatidiform mole, and no metastatic lesions were seen in intra-abdominal organs.

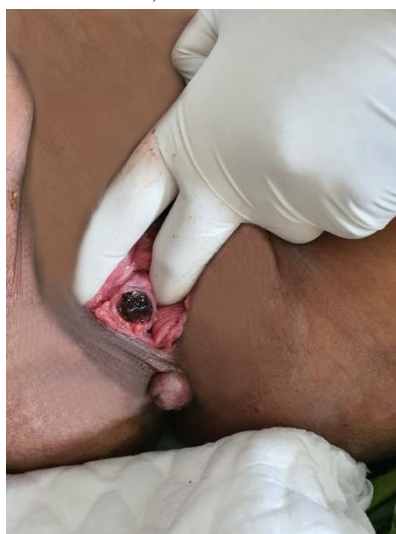

Figure 2. Mass in the vagina after the first cycle of EMACO chemotherapy

MANAGEMENT

The patient was given the EMACO (etoposide, methotrexate, actinomycin D, cyclophosphamide, vincristine) regimen.

After being given EMACO chemotherapy in the first cycle, the complaints of vaginal bleeding disappeared, but the mass in the vagina was still there. Thus, EMACO chemotherapy

Gestational Trophoblastic Disease Metastasized to the Vagina: Case Report

was continued. In the third cycle of chemotherapy, the mass in the vagina disappeared, and the β -hCG level was 228,388 mIU/mL. At the tenth EMACO chemotherapy, the β -hCG

level was found to be 18.3 mIU/mL, but because the β -hCG level was still detectable and the β -hCG level was a plateau, it was decided to perform a total hysterectomy.

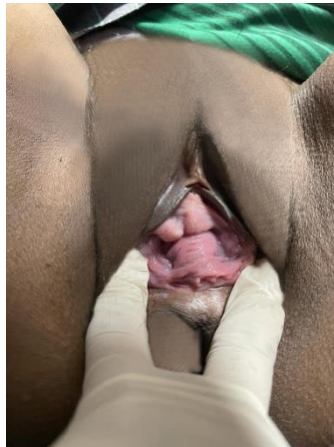

Figure 3. No mass seen after the third cycle of EMACO chemotherapy

DISCUSSION

The gestational trophoblastic disease consists of benign and malignant conditions arising from an abnormal pregnancy. These diseases are also a heterogeneous group of pregnancy-associated growths, often referred to as tumors. Benign conditions include partial and complete moles. Meanwhile, malignant conditions are like choriocarcinoma. In general, complete moles consist of hydropic villi to semi-transparent vesicles of varying sizes in the absence of a normal placenta. Complete moles also have evidence of abnormal villi or no villi at all.⁵

In this case, the patient experienced bleeding in the first and second trimesters. Her uterus was larger than her gestational age, and she had hyperemesis. In this regard, vaginal bleeding at the age of 6-16 weeks is the most common presentation of moles, occurring in 80-90% of cases.² On ultrasound examination, it will show that there is no fetus, a cystic placenta, and the gestational sac is deformed or abnormal, such as spontaneous abortion.¹ In pregnancy with the gestational trophoblastic disease, it ranges from subclinical hyperthyroidism to thyrotoxicosis and thyroid storm.² In this case, the patient had a thyroid storm characterized by thyroid hormone marker (ft4) of >100 and thyroid-stimulating hormone (TSHs) of 0.015, both of which are clinical features of a thyroid storm. In addition, there was also an increase in β -HCG levels compared to normal pregnancy ($>100,000$ mIU/mL). In this patient, the β -HCG examination result was more than 1,000,000 mIU/mL, so judging by the high β -HCG number, it also indicated the presence of malignancy.²

In addition, the gestational trophoblastic disease is divided into non-metastatic and metastatic. In those that metastasize, it mostly invades outside of the uterus, where it spreads more often via hematogenous. The lung is the most common site for metastases from gestational trophoblastic disease, followed by the vagina, fallopian tubes, ovaries,

liver, spleen, kidney, intestine, and brain. The prognosis will be worse if the metastases have reached the liver and brain.⁶

Vaginal metastases occur in 30% of patients with metastatic gestational trophoblastic disease, the second most common after lung metastases. If there is a vaginal lesion, the vaginal area will be filled with a venous plexus. Therefore, the patient will usually experience significant, recurrent, and uncontrolled bleeding. The incidence of vaginal metastases was 8.6% in a study conducted by Vidyadhar B. Bangal et al. It is where the metastases of these tumors were often found on the anterior wall of the vagina, and the majority of patients complained of bleeding and rupture.⁴

In this case, the metastatic lesion was >3 cm, considered a high-risk factor because of the tendency to bleed. Thus, it is recommended for such patients to receive combination chemotherapy (EMA-CO) and even those with scores less than 6. The prognosis in these patients is also worse concerning the size of the metastatic lesion. Vaginal metastatic lesions may also rupture during the examination, or there may be a history of speculum use. In fact, it can also be invisible because the lesions are too small or the patient has no symptoms. Thus, it can be noted in patients with gestational trophoblastic disease that physical examination of the vagina or use of a speculum in all directions must be very careful.⁷

On the other hand, a biopsy is not recommended. In a study by Berkowitz and Wong, it was stated that a biopsy should not be performed in patients with gestational trophoblastic disease and metastases to the vagina. If metastases are found in the fertile urethra and fornix, bleeding cannot be controlled, requiring conventional therapy, and the internal iliac artery must be ligated or embolized.⁷

Moreover, the process of metastases or spread routes of cancer cells occurs in several ways, including *percontinuitatum*, in which cancer cells leave the organ where they grow and then spread to surrounding structures;

Gestational Trophoblastic Disease Metastasized to the Vagina: Case Report

lymphogenic, i.e., cancer cells spread following the lymph flow and cause metastasis in regional lymph nodes; hematogenous, i.e., cancer cells enter the veins and spread to other organs of the body; transluminal, i.e., cancer cells spread through the respiratory tract, digestive tract, and urinary tract; *transcelomic*, i.e., cancer cells spread by penetrating the surface of the peritoneal, pleural, pericardial, or subarachnoid space; iatrogenic, i.e., cancer cells separated from the parent tumor due to surgery, trauma, or the massage process. In this regard, the gestational trophoblastic disease is a highly invasive tumor that easily spreads to other organs, including the vagina.⁸ Metastases to other organs often occur in the early stages of the disease with a hematogenous pattern of spread.^{8,9} Gestational trophoblastic disease also tends to metastasize via the hematogenous route because trophoblast cells have an affinity for blood vessels.¹⁰

Currently, treatment with single-agent methotrexate is recommended for low-risk diseases, while an intensive combination regimen, including EMACO (Etoposide, Methotrexate, Actinomycin D, Cyclophosphamide, and Vincristine (Oncovin)) is recommended for medium or high-risk disease.^{4,5} Similarly, the gestational trophoblastic disease that has metastasized to the vagina is considered a high-risk factor, and therefore, combination therapy (EMA-CO) is recommended as first-line therapy.⁷ Hysterectomy may also be considered in women who are >40 years of age and wish to be sterilized. This procedure is also given to patients who have heavy and uncontrolled bleeding. In addition, inserting a tampon into the vagina can also stop bleeding.⁴

CONCLUSION

The presence of vaginal metastases in gestational trophoblastic disease, which is >3 cm in size, is an important prognostic factor. If there is a high risk that can cause heavy bleeding, the patient is given combination chemotherapy, regardless of staging and scoring, being the right choice. Therefore, the diagnosis and classification of gestational trophoblastic disease help determine appropriate management, thereby increasing patient treatment success. In the future, further studies should be considered and recommended to evaluate this problem.

REFERENCES

- I. Ngan HYS, Seckl MJ, Berkowitz RS, et al. Update on the diagnosis and management of gestational trophoblastic disease. *Int J Gynecol Obstet.* 2015;131:S123-S126. doi:10.1016/j.ijgo.2015.06.008
- II. Carly Blick M, E., Kraftin Schereyer M. Gestational Trophoblastic Disease Induced Thyroid Storm., 5 (2019)
- III. Emily Du a', Melissa Perez a, Tabettha Harken JHT. Vaginal Metastasis of Gestational Trophoblastic Neoplasia Resulting in Hemorrhage: A Case Report., 3 (2020).
- IV. Vidyadhar B. Bangal*1, Kunaal K. Shinde2, Satyajit P. Gavhane3 RKS. Gestational Choriocarcinoma of Uterus with Vaginal Metastasis. 4, 3 (2013).
- V. Ning F, Hou H, Morse AN, Lash GE. Understanding and management of gestational trophoblastic disease [version 1; peer review: 2 approved]. *F1000Research.* 2019;8:1-8. doi:10.12688/f1000research.14953.1
- VI. Jingnan Li 1 , Yu Wang 1 , Bingjian Lu , Weiguo Lu3 XX and YS. Gestational Trophoblastic Neoplasia with Extrauterine Metastasis but Lacked Uterine Primary Lesions: A Single Centre Experience and Literature Review. *Gestation Trophobl Neoplasia with Extrauterine Metastasis but Lacked Uterine Prim Lesions A Single Cent Exp Lit Rev.* Published online 2022:11.
- VIII. Fatemeh G, Shohreh B, Azamolsadat M, et al. Assessment of the response to chemotherapy in gestational trophoblastic neoplasia with vaginal metastases. *Arch Gynecol Obstet.* 2008;278(4):315-318. doi:10.1007/s00404-008-0588-5
- IX. GYU-SIK KIM K-AH and K-CC. A Promising Therapeutic Strategy for Metastatic Gestational Trophoblastic Disease: Engineered anticancer gene expressing stem cell to selective target choriocarcinoma (Review). Published online 2018:7.
- X. Liu H, Xiao YD, Peng SP, Zhou SK, Liu J. Pituitary metastasis of choriocarcinoma: A case report. *Oncol Lett.* 2016;11(2):1517-1520. doi:10.3892/ol.2016.4088
- XII. Milenković V, Lazović B, MačVanski M, Jeremić K, Hrgović Z. Clinical outcome of a FIGO stage IV gestational choriocarcinoma. *Case Rep Oncol.* 2013;6(3):504-507. doi:10.1159/000353626