

## Review of Therapeutic Management in Necrotizing Pancreatitis and Case Presentation at a Secondary Care Level

Rosalía Karina González Pérez<sup>\*1</sup>, María de los Ángeles Martínez Ferretiz<sup>2</sup>

<sup>1</sup>Fourth-year General Surgery Resident, Department of General Surgery, General Hospital of Cancun. Postgraduate program, Faculty of Medicine, Autonomous University of Yucatán.

<sup>2</sup>Course Director of General SurgeCry Specialty, General Hospital of Cancun.

### ABSTRACT

Acute pancreatitis (AP) is an inflammatory disease of the pancreatic parenchyma, resulting from the premature activation of pancreatic zymogens, with local and systemic repercussions. It represents one of the main causes of hospital admission for gastrointestinal pathologies, with predominant etiologies such as biliary (32-49%) and alcohol consumption (20-31%). Management depends on the severity and complications present. Although open laparotomy was historically used, minimally invasive techniques have demonstrated superiority in terms of clinical outcomes. Surgical options include open, percutaneous, laparoscopic and endoscopic necrosectomy, the selection of which depends on factors such as the availability of resources, surgical skills and the clinical condition of the patient

### ARTICLE DETAILS

**Published On:**  
**23 December 2024**

**Available on:**  
<https://ijmscr.org/>

### INTRODUCTION

Acute pancreatitis (AP) is defined as inflammation of the pancreatic parenchyma resulting from the inappropriate intraparenchymal activation of pancreatic zymogens, leading to both local and systemic complications. It has a high global prevalence, with biliary origin accounting for 32-49% of cases and alcoholic origin for 20-31%. It is a common cause of hospital admissions for gastrointestinal diseases and requires multidisciplinary management, especially in severe cases. Acute pancreatitis can follow different courses: an interstitial edematous form, which generally has no serious consequences, and a necrotic form associated with severe disease. The former accounts for 80% of cases and typically follows a self-limiting course, while the latter constitutes 20% and is always linked to severe illness.

Initially, an open surgical approach, such as laparotomy, was considered appropriate. However, significant studies have demonstrated that the dynamic evolution of minimally invasive techniques yields better outcomes.

### ETIOLOGY

**Biliary:** This is the most common cause of AP. Approximately 7% of patients with gallstones develop pancreatitis during their lifetime. Smaller stones (<5 mm) are more frequently associated with acute pancreatitis due to their increased likelihood of migrating into the ducts.

**Alcohol:** Alcohol consumption is the second most common cause of acute pancreatitis worldwide and the leading cause of chronic pancreatitis. It is suspected in cases of alcohol intake exceeding 50 g/day for at least five years. Alcohol-related pancreatitis is often associated with tobacco use in up to 90% of cases.

**Dyslipidemia:** Hypertriglyceridemia accounts for 2%-7% of AP cases. Although significantly elevated triglyceride levels (>1000 ng/mL) are commonly observed, recent studies suggest that even moderate elevations can increase the risk. Triglyceride levels are often very high during the initial episode, but subsequent episodes may be triggered by smaller elevations. Triglyceride levels may appear falsely low if the patient has been fasting due to pain, requiring retesting post-recovery. Patients with familial combined hyperlipidemia or familial hypertriglyceridemia are at higher risk, particularly if they also have secondary factors such as excessive alcohol consumption, poorly controlled diabetes, or pregnancy. Familial chylomicronemia syndrome poses a significant risk, with up to a 76% lifetime incidence even without other secondary risk factors.

**Drugs:** The association between certain medications and pancreatitis is rare (<5% of cases). Medications most strongly associated with pancreatitis include didanosine, asparaginase, azathioprine, valproic acid, 6-mercaptopurine, and mesalamine.

## Review of Therapeutic Management in Necrotizing Pancreatitis and Case Presentation at a Secondary Care Level

Pancreatic Tumors: Approximately 15% of pancreatic tumors may present with pancreatitis due to extrinsic mechanical obstruction of the ducts. Adenocarcinoma is the leading culprit and should be suspected in patients over 40 years old with poor response to medical treatment.

Alterations in the sphincter of Oddi have also been linked to recurrent pancreatitis. Interventions in this area carry a risk of triggering inflammation and should only be performed in specialized therapeutic endoscopy centers.

### Rare Causes Include:

ETIOLOGY	FREQUENCY
AUTOIMMUNE	<1 %
TRAUMA	<1%
INFECTION	<1%
ERCP	5-10% OF POSTOPERATIVE PATIENTS
POST-OPERATED	DEPENDING ON THE TYPE OF SURGERY. 5-10% WITH CARDIOPULMONARY BYPASS. PANCREATIC ISCHEMIA.
PANCREATIC DUCT OBSTRUCTION	RARE

**Table 1. Less common etiologies of pancreatitis**

Trauma. Penetrating trauma: Can damage the pancreas, often accompanied by concurrent injury to adjacent abdominal organs. Blunt trauma: Causes injury through deceleration or compression mechanisms against vertebrae, leading to anything from minor contusions to complete lacerations. These injuries are associated with pancreatic duct rupture and peritoneal release of enzymatic contents. In cases of suspected pancreatic trauma, Endoscopic Retrograde Cholangiopancreatography (ERCP) may be used to rule out ductal injuries.

Other Causes: Hemodynamic alterations: Conditions like extensive burns, which induce a state of shock, can result in pancreatic damage through ischemia. (14)

### DIAGNOSIS AND CLASSIFICATION

Diagnosing pancreatitis requires meeting two of the following three criteria:

a) Clinical: Severe, characteristic epigastric pain that is piercing, radiates to the back, and has a sudden onset.

b) Biochemical:

- Amylase: The pancreas contributes only 40% of serum amylase levels, with the rest originating from other glandular tissues, such as the salivary glands. Levels rise within 4 hours, peak at 48 hours, and then decline.

- Lipase: A specific marker for pancreatic inflammation, as it is not produced by other organs. Levels rise within 4-6 hours, peak at 48 hours, and remain elevated for up to 14 days.

c) Radiological: Computed tomography (CT): The optimal timing for CT imaging is 72 hours after symptom onset, allowing necrosis to become visible. Early imaging risks underestimating the condition. (14)

### PROGNOSTIC MARKERS

C-reactive protein (CRP): Primarily prognostic, with sensitivity ranging from 40-60% and specificity of 90%.

Other markers:

- Interleukin-6 (IL-6): Released by macrophages in response to tissue damage, useful for predicting severity at 24–48 hours.
- Interleukin-8 (IL-8): Associated with the neutrophilic inflammatory response.
- Tumor Necrosis Factor-alpha (TNF- $\alpha$ ): Like IL-6, predicts severity.
- Procalcitonin: A useful severity prognostic factor, with sensitivity and specificity between 85% and 97%.

### IMAGING STUDIES

Contrast-enhanced Computed Tomography (CT): Offers up to 90% sensitivity and specificity. Reserved for cases with diagnostic uncertainty or when patients show no improvement within the first 48–72 hours. CT findings provide the basis for the Balthazar classification, which evaluates the severity of pancreatitis.

## Review of Therapeutic Management in Necrotizing Pancreatitis and Case Presentation at a Secondary Care Level

	FINDINGS	SCORE
A	Normal Pancreas	0
B	Local or diffuse enlargement of the pancreas. Irregular contours, heterogeneous attenuation. Dilation, without evidence of peripancreatic disease.	1
C	Intrinsic pancreatic alterations, associated with increased density and inflammatory changes in fat.	2
D	Single ill-defined liquid collection	3
E	Two or more ill-defined fluid collections, presence of gas	4

NECROSIS	SCORE
0%	0
<30%	2
30-50%	4
>50%	6

TOTAL SCORE	ÍNDICE DE SEVERIDAD
0-3	LOW
4-6	MEDIUM
7-10	HIGH

**Table 2. Balthazar classification, score and index of severity**

Classification and Prediction of Acute Pancreatitis. Variations in the clinical course of pancreatitis have led to the development of various classifications. The most internationally accepted system is the 2012 Atlanta revision, which standardized terminology.

Morphological Classification (Atlanta, 2012)

1. Interstitial Edematous Pancreatitis: Non-necrotizing inflammation. CT: focal or diffuse thickening, homogeneous or heterogeneous enhancement, striated peripancreatic fat, and small fluid collections.

2. Necrotizing Pancreatitis: Occurs in 5-10% of acute pancreatitis cases. CT: hypodense areas indicative of necrosis. Variable natural history: can remain solid or liquefy, become infected, or resolve.

Atlanta divides the collections that appear as complications based on content and evolution time (considering the onset of symptoms):

- Acute Peripancreatic Fluid Collection: Develops within the first 4 weeks. Adjacent to the pancreas, containing only fluid with no defined wall.

- Pseudocyst: Persistent collection >4 weeks. Features a defined wall and solid content.

- Acute Necrotic Collection: Affects pancreatic and peripancreatic parenchyma. CT shows multiple septated collections with heterogeneous density.

- Encapsulated Necrosis: Necrotic tissue surrounded by a hyperenhancing capsule of reactive inflammatory tissue.

### TREATMENT

Treatment of pancreatitis depends on the severity of the disease and the presence or absence of complications.

Fluid Resuscitation

Initial management always emphasizes the maintenance of intravenous fluids as a pillar of treatment, especially in the first 1,2-24 hours. Hypovolemia in pancreatitis occurs due to intravascular volume depletion and third space leak. Crystalloid resuscitation is the most accepted in most

contexts. It is suggested to start with a bolus replacement of 10 ml/kg due to hypovolemia data, and continue with an infusion of 1.5 ml/kg/hour (according to the Waterfall scheme) to avoid fluid overload, with evaluation at 3 hours and subsequently at 12 hours, 24 hours and 48 hours.

Antibiotic Therapy

Antibiotics are only administered if there is clinical suspicion or evidence of infected necrosis, not prophylactically. Prophylactic antibiotic use has not shown benefits in preventing necrosis infection or reducing mortality.

- Therapy should be guided by the sensitivity of isolated organisms in the local population.

- For cases with >50% necrosis, prophylactic antibiotics may be considered due to the high risk of infection.

- Empirical Therapy: Monotherapy with carbapenems tends to be effective as empirical therapy

Analgesia

Pain management becomes important because it tends to be the main reason for consultation; depending on the intensity, respiratory function can be affected by causing restriction of the movement of the abdominal wall and therefore the ventilatory mechanics.

Nutrition

Previously, it was recommended that patients fast in order to reduce stimulation of exocrine secretion from the pancreas. Nowadays, early initiation of enteral nutrition is considered beneficial, in mild cases within the first 24 hours. In moderate or severe cases, adequate nutrition reduces the risk of infection from peripancreatic necrosis and organ failure. Benefits of enteral over parenteral nutrition: Reduced hospital stay and cost, protection of the intestinal mucosal barrier and reduced bacterial translocation. Among the complications that developed, the following stand out: pancreatic fistula and enterocutaneous fistula. (2)

### Surgical Indication

It is recommended to avoid any intervention during the first two weeks of severe pancreatitis due to the high mortality risk; instead, a delay of 3-5 weeks is preferred. Exceptions for intervention include confirmed necrosis infection and persistent organ failure with walled-off necrosis. The treatment for infected necrosis is surgical debridement (necrosectomy), always prioritizing minimally invasive techniques whenever possible (e.g., percutaneous drainage, transgastric endoscopic drainage, etc.). Percutaneous drainage and endoscopic drainage are evolving techniques and are considered viable treatment options in facilities with the necessary skills and expertise.

Invasive surgery has become the primary treatment for infected pancreatic necrosis, with a “step-by-step” approach, starting with percutaneous catheter drainage, minimally invasive surgery (laparoscopy) and ultimately open surgery. As for washing with saline solution, in different studies, it was performed on an average of 3 to 5 liters with drainage depending on its duration until clinical and biochemical improvement compatible with the clarity of the drainage was shown. (2)

### CLINICAL CASE PRESENTATION.

A 43-year-old male, a farmer by occupation, with no significant medical history for the current pathology.

The patient began with a 7-day history (01/21/24) characterized by stabbing and burning abdominal pain with an intensity of 10/10 on the visual analogue pain scale (VAS), which was accompanied by nausea and vomiting on multiple occasions with gastrobiliary characteristics, which ultimately led to intolerance to the oral route. He visited several physicians who prescribed antibiotics and analgesics, without specifying further. He denied any improvement and had a fever of 38.3 C, which is why he went to the Felipe Carrillo Puerto general hospital, where a surgical protocol was started for a condition suggestive of appendicitis complicated by perforation. With a clinical diagnosis of probable intestinal perforation and laboratory evidence of a systemic inflammatory response, a transfer to the Cancun general hospital was requested. In our hospital we received a patient with a diagnosis of acute appendicitis complicated by probable intestinal perforation. Upon arrival he was in the following condition:

Physical examination: hemodynamically stable, neurologically intact, conscious, oriented, with a painful facies, dehydrated oral mucosa, slight paleness of the integuments, no jaundice, cylindrical neck, central and mobile trachea, not painful to move, with decreased left basal vesicular murmur. Rhythmic heart sounds without murmurs or aggregates, globose abdomen due to great abdominal distension, absent peristalsis in all quadrants, pain on palpation predominantly in the epigastrium, mesogastrium and right iliac fossa, positive rebound, involuntary muscle rigidity, positive McBurney sign, negative Murphy, negative

bilateral Giordano, with clear signs of peritoneal irritation, with involuntary muscle resistance, intact, functional extremities, with adequate capillary filling.

Labs on admission (01/28/2024): amylase 48, lactate dehydrogenase 215, sodium 132, potassium (K) 3.8, chlorine (cl) 97, glucose 136, creatinine (cr) 0.8, blood type and Rh o+, hemoglobin (hb) 9.86, hematocrit (hto) 29%, white blood cells (WBC) 28,200, platelets 395, neutrophil percentage 88%, erythrocyte sedimentation rate (ESR) 25, C-reactive protein (crp) <0.6.

A simple abdominal CT scan was performed on 01/28/2024: We do not have a written report. Significant dilatation of intestinal loops is observed, in addition to peripancreatic fatty striation, pancreas with loss of its normal anatomy, and the presence of gas inside it is striking, findings compatible with Balthazar E. pancreatitis. The presence of a small left pleural effusion is also observed.

Finally, after analyzing the case, and with a high suspicion of necrotizing pancreatitis due to the clinical picture and tomographic image (mainly highlighting the presence of gas in the pancreas), a surgical protocol is carried out for exploratory laparotomy at this time with surgical urgency. Availability of blood products is requested. We begin intense fluid resuscitation according to international guidelines, with Hartmann solution, double broad-spectrum antibiotic regimen and analgesia. The case is reported to the intensive care unit (ICU) due to a high probability of requiring hospitalization. The patient is not exempt from complications. Prognosis: poor for life and function.

The patient was admitted to the operating room with a diagnosis of necrotizing pancreatitis. Exploratory laparotomy was performed, pancreatic necrosectomy was added, and the following findings were reported: necrosis of the pancreatic body, obtaining 100 gr of necrotic tissue corresponding to the body of the pancreas, 100 cc of fetid purulent exudate, a friable transverse colon was observed, and a plastron at the hepatic flexure. Multiple lavages with irrigation were performed on the remaining pancreatic tissue with a total of approximately 5 liters of 0.9% saline solution. Two Saratoga-type drains were placed into the transcavity of the epiplons and through both parietocolic slides. The patient was admitted to the ICU with a reserved prognosis.

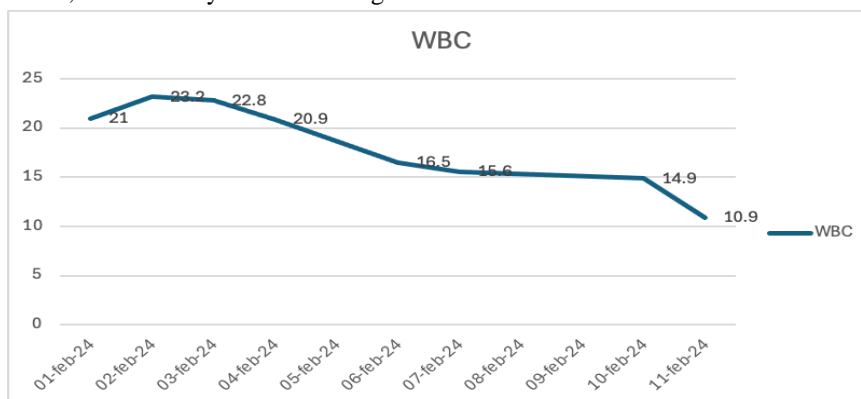
After the intervention, he remained in the ICU for approximately 72 hours and after successful extubation, he was transferred to the hospitalization floor under the care of General Surgery. The start of the enteral route with a liquid diet is established during the first 24 hours after extubation, after finding an adequate level of consciousness, with adequate tolerance and progression. He is kept under close surveillance with serial laboratories, particularly monitoring the levels of hemoglobin (HB), leukocytes (WBC), % polymorphonuclear cells (% PMN), glucose (gluc) and potassium (K), maintenance fluid therapy, remains on a broad-spectrum antibiotic regimen, completing a full 10 days on carbapenems. Daily lavages are added with approximately

## Review of Therapeutic Management in Necrotizing Pancreatitis and Case Presentation at a Secondary Care Level

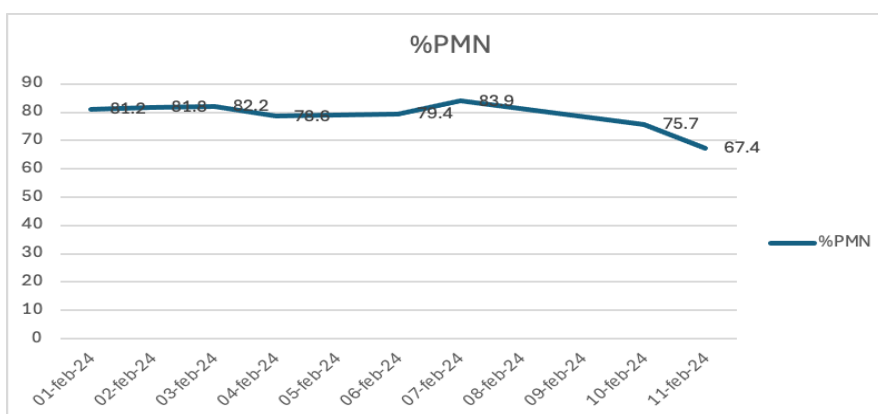
2-3 liters of 0.9% saline solution, through a Saratoga-type drain. During the immediate postoperative period, he develops left pleural effusion secondary to the acute pancreatitis process, warranting placement of an endopleural seal (SEP). However, the patient's progress was favorable, with the SEP being removed 72 hours after its placement when the effusion resolved, from which a total of 200 cc was obtained.

In serial paraclinical tests, a tendency towards normal figures for each category was observed, with the only attention being

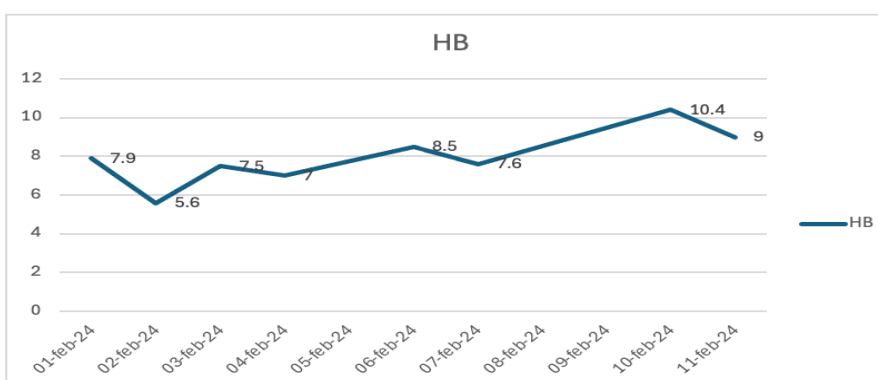
drawn to glucose figures greater than 100 mg/dl in the last controls. Finally, the patient remained in hospital for a total of ten days until his discharge and was subsequently sent for follow-up in the outpatient clinic. During his first subsequent consultation, a pathology report was obtained describing the specimen as a pancreatic body, acute inflammation, marked hemorrhage, extensive coagulative necrosis of the pancreatic parenchyma and peripancreatic adipose tissue; consistent with necrotizing pancreatitis. Serial control laboratories:



Graph. 1 White blood cell count (WBC)

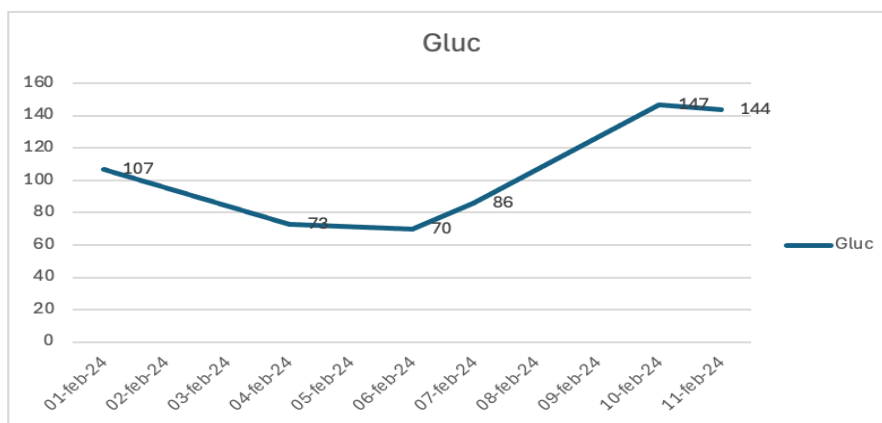


Graph 2 Percentage of Neutrophils (PMN)



Graph 3 Hemoglobin levels





Graph. 4 Serum glucose levels

**DISCUSSION**

In patients with pancreatitis who develop necrotizing disease, there are two peaks of mortality: systemic inflammatory response syndrome and multiple organ dysfunction syndrome. When a secondary infection also occurs in the necrotic tissue, it easily leads to sepsis and consequently to organ failure, which increases the mortality rate from 15% to 30%.

Indications for intervention include high suspicion or already documented infection of said necrosis, persistent organ failure, septated collections, etc. Surgical options include: open necrosectomy, percutaneous necrosectomy, minimally invasive necrosectomy, and endoscopic necrosectomy through the stomach. No therapeutic approach is ideal to use in all cases; the decision depends on the availability of resources, surgical skill, and often results from the combination of several therapies depending on the patient's condition and the environment in which care is intended to be provided.

When choosing the open alternative, necrosectomy (debriding all necrotic areas by digital dissection) and the insertion of multiple drains to control the leakage of pancreatic tissue and at the same time allow the continuous flow of infected and necrotic material are included.

Regarding the laparoscopic approach, some of its advantages are considered:

- Excellent visualization and access to all quadrants of the abdomen, helping with the debridement and adequate drainage of collections.

- Reduction in complications related to extensive wounds.

- Decrease in respiratory morbidities that can be aggravated after a laparotomy.

However, some disadvantages stand out:

- Risk of generalized contamination of the peritoneal cavity.

- Possibility of inadequate debridement, due to restrictions on laparoscopy and the surgeon's skill.

It may be associated with a higher risk of intestinal injuries or hemorrhages if the necessary training is not available.

For the correct choice of approach, we emphasize that the following must be taken into account: the location of the necrosis, and the ability to access transperitoneally for

necrosis in the head and body region, or the current trend, which leans toward laparoscopic necrosectomy but with a retroperitoneal approach, with the advantage of limited contamination of the peritoneal cavity and lower risk of intestinal injury and complications of the abdominal wall. A good option that, however, is conditioned by a longer learning curve. (2)

In relation to the case presented, the therapeutic alternatives are restricted mainly by the material and technological resources that characterize a second level hospital. However, it is possible to achieve effective resolution of the critical phase and postoperative care, largely thanks to the early identification of this pathology, the rapid evaluation of available therapeutic options in decision-making. All this while having to deal with considerably high mortality rates such as those reported in more invasive interventions such as open laparotomy necrosectomy.

**CONCLUSION**

Knowledge of a pathology as complex as acute pancreatitis and its complications requires the involvement of a multidisciplinary team that includes gastroenterologists, intensivists, surgeons, and interventional radiologists who together allow for a correct evaluation and can safely determine the therapeutic approach, the appropriate time for intervention, and the type of interventions that can be offered to the individual patient.

Within our environment, as a second level care hospital, despite not having the equipment available on any shift to be able to offer any minimally invasive alternative, it seems promising that the few cases that have been presented, in a very similar way to the one we already mentioned; with ambiguous symptoms, with suspicion of probable perforation and without any further study protocol than blood tests. By completing the laboratory studies and elucidating that it is not only a case of acute pancreatitis, but a complicated variant (with necrosis and infection), an open surgical alternative can be offered, taking into account the significant increase in the percentage of morbidity and mortality. It is demonstrated that care was provided with the best standards that the state can

offer, concluding with a favorable result, at least during the first year of follow-up after discharge.

It is definitely necessary to continue the follow-up of cases such as the one already presented, for a longer period of time and to be able to identify late complications, in order to have a clearer vision of the results. For the moment, the resolution of this type of cases becomes a reality by having a multidisciplinary team that continues to be constantly updated and trained.

### REFERENCES

- I. Arvanitakis, M., Ockenga, J., Bezmarevic, M., Gianotti, L., Krznarić, Ž., Lobo, D. N., Löser, C., Madl, C., Meier, R., Phillips, M., Rasmussen, H. H., Van Hooft, J. E., & Bischoff, S. C. (2020). ESPEN guideline on clinical nutrition in acute and chronic pancreatitis. *Clinical Nutrition (Edinburgh, Scotland)*, 39(3), 612–631. <https://doi.org/10.1016/j.clnu.2020.01.004>
- II. Clark, C. J., Ray, J. W., Pawa, S., Jahann, D., McCullough, M., Miller, P., Mowery, N., Miller, M., Xiao, T., Koutlas, N., & Pawa, R. (2024). A location-based anatomic classification system for acute pancreatic fluid collections: Roadmap for optimal intervention in the step-up era. *Surgery Open Science*, 18, 1–5. <https://doi.org/10.1016/j.sopen.2024.01.008>
- III. Ma, Y., Ong, F., Hew, S., Swan, M., Devonshire, D., & Croagh, D. (2024). Repetitive endoscopic drainage as initial intervention is safe and effective for early treatment of pancreatic necrotic collections. *ANZ Journal of Surgery*, 94(5), 881–887. <https://doi.org/10.1111/ans.18852>
- IV. Maurer, L. R., & Fagenholz, P. J. (2023). Contemporary surgical management of pancreatic necrosis. *JAMA Surgery*, 158(1), 81–88. <https://doi.org/10.1001/jamasurg.2022.5695>
- V. Niu, C. G., Zhang, J., Zhu, K. W., Liu, H. L., Ashraf, M. F., & Okolo, P. I., 3rd. (2023). Comparison of early and late intervention for necrotizing pancreatitis: A systematic review and meta-analysis. *Journal of Digestive Diseases*, 24(5), 321–331. <https://doi.org/10.1111/1751-2980.13201>
- VI. Palumbo, R., & Schuster, K. M. (2024). Contemporary management of acute pancreatitis: What you need to know. *The Journal of Trauma and Acute Care Surgery*, 96(1), 156–165. <https://doi.org/10.1097/TA.0000000000004143>
- VII. Rayman, S., Jacoby, H., Guenoun, K., Oliphant, U., Nelson, D., Kaiser, A., & Sucandy, I. (2023). Diagnosis and contemporary management of necrotizing pancreatitis. *The American Surgeon*, 89(11), 4817–4825. <https://doi.org/10.1177/00031348231156781>
- VIII. Sagar, A. J., Khan, M., & Tapuria, N. (2022). Evidence-based approach to the surgical management of acute pancreatitis. *The Surgery Journal*, 8(4), e322–e335. <https://doi.org/10.1055/s-0042-1758229>
- IX. Samanta, J., Dhar, J., Muktesh, G., Gupta, P., Kumar-M, P., Das, A., Agarwala, R., Bellam, B. L., Chauhan, R., Kumar, K. H., Yadav, T. D., Gupta, V., Sinha, S. K., Kochhar, R., & Facciorusso, A. (2022). Endoscopic drainage versus percutaneous drainage for the management of infected walled-off necrosis: a comparative analysis. *Expert Review of Gastroenterology & Hepatology*, 16(3), 297–305. <https://doi.org/10.1080/17474124.2022.2047649>
- X. Sato, T., Saito, T., Takenaka, M., Iwashita, T., Shiomi, H., Fujisawa, T., Hayashi, N., Iwata, K., Maruta, A., Mukai, T., Masuda, A., Matsubara, S., Hamada, T., Inoue, T., Ohyama, H., Kuwatani, M., Kamada, H., Hashimoto, S., Shiratori, T., ... WONDERFUL study group in Japan, collaborators. (2023). WONDER-01: immediate necrosectomy vs. drainage-oriented step-up approach after endoscopic ultrasound-guided drainage of walled-off necrosis-study protocol for a multicentre randomised controlled trial. *Trials*, 24(1), 352. <https://doi.org/10.1186/s13063-023-07377-y>
- XI. Sivakumar, S. G., Sekaran, M., Muthukrishnan, S., Natesan, A. V., Nalankilli, V. P., Senthilnathan, P., & Palanivelu, C. (2024). Laparoscopic necrosectomy for acute necrotising pancreatitis: Retrospective analysis of a decade-long experience from a tertiary centre. *Journal of Minimal Access Surgery*, 20(2), 127–135. [https://doi.org/10.4103/jmas.jmas\\_215\\_22](https://doi.org/10.4103/jmas.jmas_215_22)
- XII. Trikudanathan, G., Wolbrink, D. R. J., van Santvoort, H. C., Mallery, S., Freeman, M., & Besselink, M. G. (2019). Current concepts in severe acute and necrotizing pancreatitis: An evidence-based approach. *Gastroenterology*, 156(7), 1994–2007.e3. <https://doi.org/10.1053/j.gastro.2019.01.269>
- XIII. Troncone, E., Amendola, R., Gadaleta, F., De Cristofaro, E., Neri, B., De Vico, P., Paoluzi, O. A., Monteleone, G., Anderloni, A., & Del Vecchio Blanco, G. (2024). Indications, techniques and future perspectives of walled-off necrosis management. *Diagnostics (Basel, Switzerland)*, 14(4), 381. <https://doi.org/10.3390/diagnostics14040381>
- XIV. Van Wieren, A., Guild, M., Raucci, N., & Meyer, S. (2022). Managing severe acute and necrotizing pancreatitis. *JAAPA: Official Journal of the American Academy of Physician Assistants*, 35(6), 15–20.

## Review of Therapeutic Management in Necrotizing Pancreatitis and Case Presentation at a Secondary Care Level

<https://doi.org/10.1097/01.JAA.0000830176.03626.15>

- XV. Zhang, H.-Y., & He, C.-C. (2024). Early endoscopic management of an infected acute necrotic collection misdiagnosed as a pancreatic pseudocyst: A case report. *World Journal of Gastrointestinal Surgery*, 16(2), 609–615.

<https://doi.org/10.4240/wjgs.v16.i2.609>

- XVI. Trikudanathan, G., Yazici, C., Evans Phillips, A., & Forsmark, C. E. (2024). Diagnosis and management of acute pancreatitis. *Gastroenterology*, 167(4), 673–688.

<https://doi.org/10.1053/j.gastro.2024.02.052>