

## Karapandzic Flap Technique

José Emiliano González Flores<sup>1</sup>, Dra. Beverly García Vontra<sup>2</sup>, María del Rayo Méndez Palacios<sup>3</sup>, Williams Antonio Barrios Garcia<sup>4</sup>, Alberto Jaramillo Sastré<sup>5</sup>, Gonzalo Santos González<sup>6</sup>, Dr. Moises Alvir Ruiz López<sup>7</sup>, Dra. María Fernanda Ramírez Berumen<sup>8</sup>, Andrea Florián Espinosa Jiménez<sup>9</sup>, Dr. Uziel Aldahir Arrazola Pereda<sup>7</sup>, Dra. Wendy Melisa Gómez Aragón<sup>7</sup>, Dr. Luis Donaldo García Romero<sup>10</sup>, Dra. Daniella Andrea Ponce de León Camargo<sup>11</sup>

<sup>1</sup>Instituto Tecnológico y de Estudios Superiores de Monterrey ITESM Campus Ciudad de México

<sup>2</sup>Universidad Anáhuac México

<sup>3</sup>Universidad Popular Autónoma del Estado de Puebla

<sup>4</sup>Instituto Superior de Ciências da Saúde Carlos Chagas, Rio de Janeiro, Brasil

<sup>5</sup>Facultad de Medicina UNAM

<sup>6</sup>Hospital general regional 251, Metepec

<sup>7</sup>Universidad autónoma Benito Juárez de Oaxaca

<sup>8</sup>Hospital General Regional No. 2 "El Marqués", IMSS Querétaro

<sup>9</sup>Escuela Superior de Medicina, Instituto Politécnico Nacional

<sup>10</sup>Hospital General Regional No. 1 IMSS Querétaro

<sup>11</sup>Universidad Anahuac de Querétaro

### ABSTRACT

The reconstruction of lip defects poses a surgical challenge, especially when malignancies affecting the oral commissure require extensive excisions leading to considerable tissue loss. Optimal reconstruction methods must restore functionality, maintain aesthetics, and harmonize with adjacent tissues. The Karapandzic flap, introduced in 1974, provides a neurovascular myocutaneous technique that safeguards essential structures while preserving lip mobility and sensation.

This report emphasizes the reconstruction of a substantial lip defect subsequent to the excision of basal cell carcinoma utilizing the Karapandzic flap. The technique offers benefits such as a single-stage procedure, maintenance of vascular and nerve networks, and enhancement of oral function with increased lip mobility. Notwithstanding possible drawbacks like temporary microstomia and asymmetry of the oral commissure, the Karapandzic flap provides enhanced functional and aesthetic results relative to alternative techniques. This method proficiently targets the intricate musculature at the oral commissure, delivering a substantial functional reconstruction while circumventing the rigidity and diminished sensation linked to alternative techniques. The Karapandzic flap is a dependable and effective method for reconstructing substantial lip defects, including those affecting the oral commissure. Although early postoperative microstomia may arise, it generally ameliorates with time, rendering this technique a commendable option for attaining optimal functional and aesthetic outcomes in lip reconstruction.

**KEYWORDS:** Karapandzic flap, lip reconstruction Preface

### ARTICLE DETAILS

**Published On:**  
**20 December 2024**

**Available on:**  
<https://ijmscr.org/>

The surgical reconstruction of lip defects presents significant challenges. Malignant lesions affecting the angle of the mouth and lip necessitate extensive excision to guarantee disease-free margins. The resultant defects are typically substantial

and frequently encompass half of the lip. Free, distant, and local flaps are accessible for the reconstruction of these defects. Distant and free flaps, however, tend to be cumbersome, necessitate an additional procedure, rarely

## Karapandzic Flap Technique

match the pigmentation of facial skin, and frequently fail to create an appropriate vermilion border and lip competence. An optimal reconstruction technique should involve a single-stage procedure that consistently substitutes the defect with analogous tissue, thereby restoring both aesthetics and functionality. Various techniques have been proposed for the reconstruction of peroral defects, including those by Abbe, Estlander, Bernard, Zisser, Gillies, and Karapandzic. In 1974, Karapandzic elucidated the application of a

neurovascular myocutaneous flap, yielding satisfactory results. The Karapandzic flap offers notable benefits; it facilitates the functional preservation of the orbicularis oris muscle, facial arteries, and sensory and motor nerves, leading to the maintenance of sensory functions, a mobile lip, and enhanced lip capacity. This report details a reconstruction utilizing a Karapandzic flap following the excision of basal cell carcinoma on the lip.

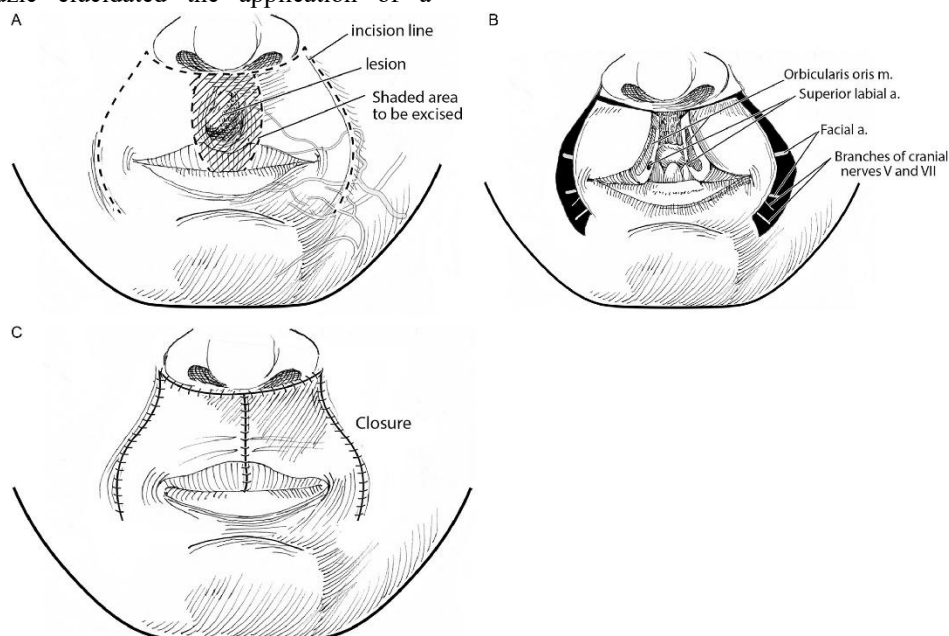


Figure 1. Surgical technique

## DISCUSSION

The management of cancer in the perioral area necessitates resection in accordance with oncological principles, while also taking into account functional and aesthetic outcomes. Nonetheless, disease-free resection is favored to preserve functionality and enhance aesthetics.

An ideal technique for lip reconstruction has not yet been determined. If the lesion on the lip affects less than one-third of it, direct closure is feasible; otherwise, valvuloplasty may

be necessary. The lip tissue comprises the epidermis, muscular layer, vermilion, and oral mucosa, exhibiting a distinctive structure not commonly found in other body regions. Consequently, utilizing adjacent lip tissues for lip reconstruction is appropriate. If the lesion encompasses over 35% of the lip, flap reconstruction is imperative, necessitating consideration of adjacent regions, including the unaffected lip (Abbe type), cheek (Gilles or Estlander type), and chin (Bernard type).

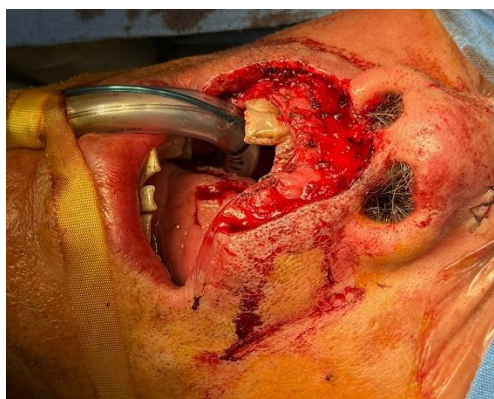

Figure 2. Preoperative image

The Karapandzic procedure is beneficial as it necessitates only one surgical intervention, can be executed swiftly after

acquisition of skills, conserves critical vascular and nerve structures, is safe, and retains lip mobility and sensation.

## Karapandzic Flap Technique

Nonetheless, the drawbacks encompass asymmetry of the oral corners and a diminishment in the overall mouth size. Concerning the asymmetry of the mouth's corners, Jackson asserted that the size of the mouth is not a significant concern. The asymmetry of the mouth corners ameliorates over time, and Jackson advocated for the Karapandzic technique over alternative lip reconstruction methods that yield rigid, unresponsive, and nonfunctional lips. The primary focus of reconstruction in this instance was the functional restoration of the oral commissure. The orbicularis oris muscle at the corner of the mouth comprises a complex structure that includes the risorius, levator anguli oris, buccinator, and depressor anguli oris muscles. Consequently, we assert that utilizing the orbicularis oris muscle, which possesses adequate muscle mass, for the functional reconstruction of the

mouth's corner was the optimal choice. Furthermore, the Abbe technique is inappropriate for the corners of the mouth. Given these factors, the Karapandzic flap technique was determined to be the most appropriate for the current case. The intact contralateral corner of the mouth serves as the basis for comparison. Regardless of the chosen lip reconstruction technique, asymmetry at the corners of the mouth will manifest. Insufficient muscle reconstruction, when the shape of the mouth is emphasized, can cause dispersion and numbness at the corners of the mouth, diminishing the effectiveness of the reconstruction. In our case, the corners of the mouth were preserved in an optimal position, and the progression was favorable with no complications, such as castration.

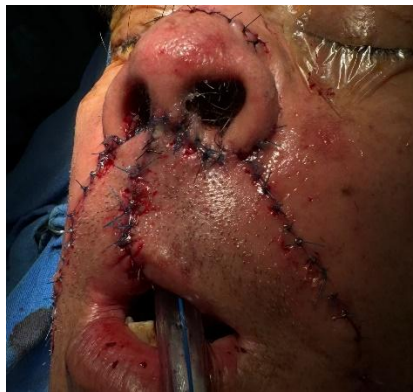

Figure 3. Postoperative image

## CONCLUSIONS

The Karapandzic flap is appropriate for reconstructing substantial lip defects, including the oral commissures, as it can be executed efficiently and securely in a single operation. This technique facilitates the preservation of the neurovascular pedicle and yields favorable functional and aesthetic results.

This technique is limited by the possibility of microstomia in the initial stages. Notwithstanding this, we contend that this represents a viable option for flap reconstruction of the lips, as the resultant microstomia tends to ameliorate over time.

## REFERENCES

- I. Suzuki, R., & Kimura, N. (2023). Lower Lip Reconstruction Using the Karapandzic Flap Technique. *Cureus*, 15(12).
- II. Lozev, I., Pidakev, I., Batashki, I., Kandathil, L. J., Oliveira, N., & Tchernev, G. (2022). Karapandzic flap as most adequate surgical approach for squamous cell carcinoma of the lower lip. *Dermatology Reports*, 14(3).
- III. 지훈김, 창은정, & 종건이. (2022). Large lower lip defect reconstruction using a Karapandzic flap: A case report and literature review. *Korean Journal of Head & Neck Oncology*, 38(2), 33-36.
- IV. García-Bañuelos, D. L., Maquita-Esquivel, K. A., Soto-Verdugo, L. A., Zamora-Inzunza, J. G., Moreno-Rubio, M. A., Barajas-Puga, J. Á., & Ramírez-Sánchez, J. M. (2024). Karapandzic flap for lower lip reconstruction. *Cirugía Plástica*, 34(3), 113-118.
- V. Namazi, M. R. (2024). Karapandzic Flap. In *Textbook of Advanced Dermatology: Pearls for Academia and Skin Clinics (Part 2)* (pp. 125-127). Bentham Science Publishers.
- VI. Mir, M., & Jain, J. (2023). Karapandzic Flap: A Versatile Technique for Lip Reconstruction.
- VII. Franco, T. Reconstrução do lábio inferior pela técnica de Karapandzic.
- VIII. Miller, L. E., & Greene, J. J. (2020). The Karapandzic flap. *Operative Techniques in Otolaryngology-Head and Neck Surgery*, 31(1), 21-25.