

Pulmonary Cysts and Spontaneous Pneumothorax in a Young Vaper with Fatal Outcome: Case Report and Literature Review

Galicia-García Luis Elías*¹, García-Hernández Jorge Alfredo², Sosa-Hernández Oscar³, Serrano-Acosta Tania Yaneli⁴, Herrera-Muñoz Viviana Marcela⁵, Corpus-Badillo Roberto⁶, William Edrei Chan Medina⁷

¹General Hospital of Zone No 50, IMSS, San Luis Potosí, Mexico.

²General Hospital of Zone No 50, IMSS, San Luis Potosí, Mexico.

³General Hospital of Zone No 50, IMSS, San Luis Potosí, Mexico.

⁴Hospital General de Zona No. 50, IMSS, San Luis Potosí, México.

⁵Central Hospital Dr. Ignacio Morones Prieto, San Luis Potosí, Mexico.

⁶Central Hospital Dr. Ignacio Morones Prieto, San Luis Potosí, Mexico.

⁷General Hospital of Zone No 2, IMSS, San Luis Potosí, Mexico.

ABSTRACT

A 24-year-old male with a history of heavy vaping developed multiple pulmonary cysts and subsequent bilateral spontaneous pneumothorax, culminating in death. Initial imaging indicated cystic damage likely caused by prolonged inhalation of toxic compounds in e-cigarettes, such as diacetyl and vitamin E acetate. This case highlights the potential link between vaping and chronic lung diseases that may progress to severe complications, contributing to the ongoing debate on vaping-associated risks and underscoring the need for further studies on its long-term effects.

KEYWORDS: Vaping, Pulmonary Cysts, Spontaneous Pneumothorax, Lung Injury, Respiratory Complications.

ARTICLE DETAILS

Published On:
23 December 2024

Available on:
<https://ijmscr.org/>

INTRODUCTION

The use of electronic cigarettes has grown considerably, especially among young people. According to the 2022 National Health and Nutrition Survey (ENSANUT) in Mexico, 2.6% of adolescents and 1.5% of adults use them¹. This popularity is driven by the perception that they are less harmful than traditional cigarettes. However, these devices contain compounds such as vitamin E acetate, which can cause severe lung damage by triggering an inflammatory response that recruits neutrophils, induces cell necrosis, and leads to acute injuries like diffuse alveolar damage and lipoid pneumonia². Other components, such as propylene glycol, glycerol, and flavorings, break down into toxic aldehydes under heat, increasing oxidative stress and the risk of chronic lung damage. Diacetyl, in particular, has been linked to bronchiolitis obliterans³. These complications were observed during the 2019 outbreak of EVALI (E-cigarette or Vaping-Associated Lung Injury), a lung disease associated with the use of electronic cigarettes and vaping products. EVALI emerged as a significant public health issue, characterized by severe lung injuries attributed to the inhalation of toxic

substances present in vaping liquids. Clinical manifestations included organizing pneumonia, diffuse alveolar damage, alveolar hemorrhage, granulomatous pneumonitis, and bronchiolitis, among others. Although the primary cause was identified as vitamin E acetate used in some vaping liquids, exposure to other components, such as diacetyl, contributes to the severity and diversity of vaping-related lung injuries.

While acute lung damage has been documented, vaping could also be associated with chronic damage, such as the formation of pulmonary cysts. Recent studies published in the *American Journal of Respiratory and Critical Care Medicine* and *Chest Journal* have suggested a link between electronic cigarettes and pulmonary cysts, pointing to cystic lung disease as a possible chronic manifestation^{4,5}. We present the case of a 24-year-old patient with a history of vaping, multiple pulmonary cysts, and fatal spontaneous pneumothorax. This case underscores the need to study chronic lung damage and the complications of these devices.

Pulmonary Cysts and Spontaneous Pneumothorax in a Young Vaper with Fatal Outcome: Case Report and Literature Review

CASE PRESENTATION

This is a 24-year-old male with no relevant medical history, born at term, and with an uneventful childhood. He had never been hospitalized or undergone complementary studies. He regularly played soccer until age 21, with no respiratory symptoms or physical limitations, and no prior pulmonary imaging was available. Regarding family history, he had a healthy older brother and no family history of lung diseases. He had completed the full childhood vaccination schedule and received three doses of the COVID-19 vaccine. He had no history of recurrent respiratory infections. The patient worked as a manager at a pizzeria, with no direct exposure to kitchen fumes or pizza oven smoke. He smoked

cigarettes for six years (4-5 cigarettes daily, a smoking index of 1.5 pack-years). He quit smoking when he began heavy use of electronic cigarettes for one year, consuming approximately five vaping cartridges per week. No use of other substances was reported.

After a year of vaping, he began experiencing non-productive cough, initially sporadic but progressively increasing in intensity and frequency, accompanied by hemoptysis and dyspnea on moderate exertion (MMRC 2). Studies conducted at a private center, including a plain chest CT scan, revealed multiple coalescent pulmonary cysts in both lower lobes (Figure 1A & 1B).

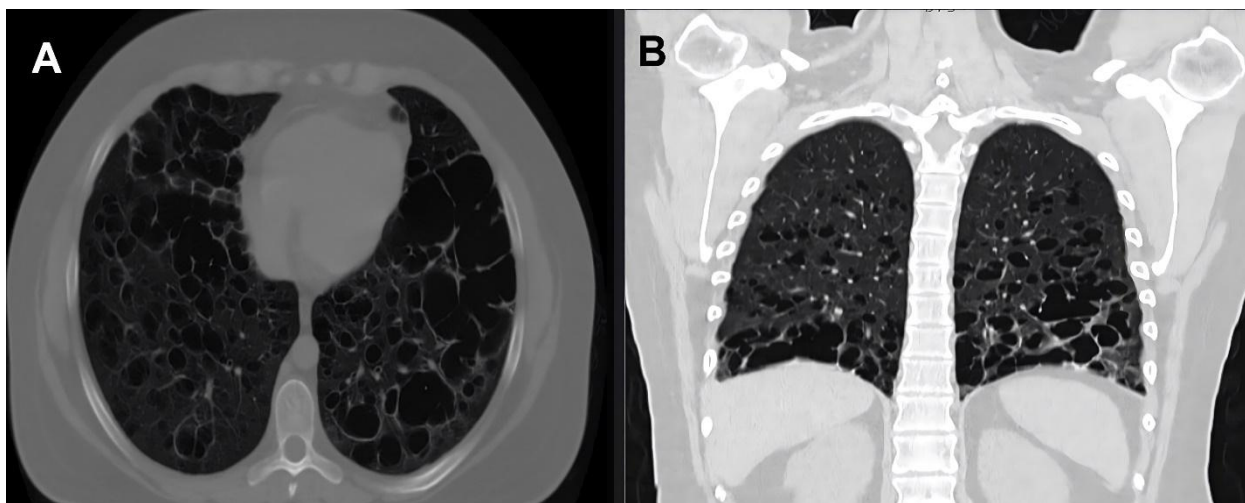


Figure 1. Chest CT scan.

(Panel A: Axial cut, Panel B: Coronal reconstruction): Multiple thin-walled pulmonary cysts diffusely distributed in both lungs, predominantly in the lower regions, with no evidence of mediastinal or hilar lymphadenopathy.

He was referred to the pulmonology department, where pulmonary function tests showed a forced vital capacity (FVC) of 70%, a forced expiratory volume in the first second (FEV1) of 51%, an FEV1/FVC ratio of 60%, and a diffusing capacity for carbon monoxide (DLCO) of 79.6%. A diagnosis of vaping-associated lung damage was made, and treatment was initiated with long-acting muscarinic antagonists, inhaled and systemic corticosteroids, with good clinical response: improvement in dyspnea, reduced cough, and increased physical capacity.

A year later, while maintaining good adherence to treatment and with minimal symptoms, he presented to our hospital with sudden-onset severe dyspnea while at rest. On admission, his oxygen saturation was 85%, improving to 90% with a reservoir mask.

Initial laboratory tests: White blood cells $12.2 \times 10^3/\mu\text{L}$, neutrophils $8.41 \times 10^3/\mu\text{L}$, lymphocytes $2.44 \times 10^3/\mu\text{L}$,

hemoglobin 14.1 g/dL, hematocrit 42.2%, MCV 88.3 fL, MCH 29.6 pg, platelets $352 \times 10^3/\mu\text{L}$, PT 12.5 seconds, INR 0.97, aPTT 27.7 seconds, glucose 131 mg/dL, urea 21.52 mg/dL, BUN 10 mg/dL, creatinine 0.95 mg/dL, uric acid 3.5 mg/dL, total cholesterol 173 mg/dL, triglycerides 205 mg/dL, total bilirubin 0.32 mg/dL, direct bilirubin 0.19 mg/dL, indirect bilirubin 0.13 mg/dL, ALT 16 U/L, AST 14 U/L, alkaline phosphatase 106 U/L, sodium 142 mmol/L, potassium 3.99 mmol/L, chloride 103 mmol/L, calcium 7.9 mg/dL, magnesium 2.07 mg/dL.

A chest CT showed bilateral spontaneous pneumothorax and worsening lung damage. Bilateral chest tubes were placed, and invasive mechanical ventilation was initiated (Figure 2A & 2B). Despite therapeutic efforts, the patient experienced progressive deterioration and died seven days after admission.

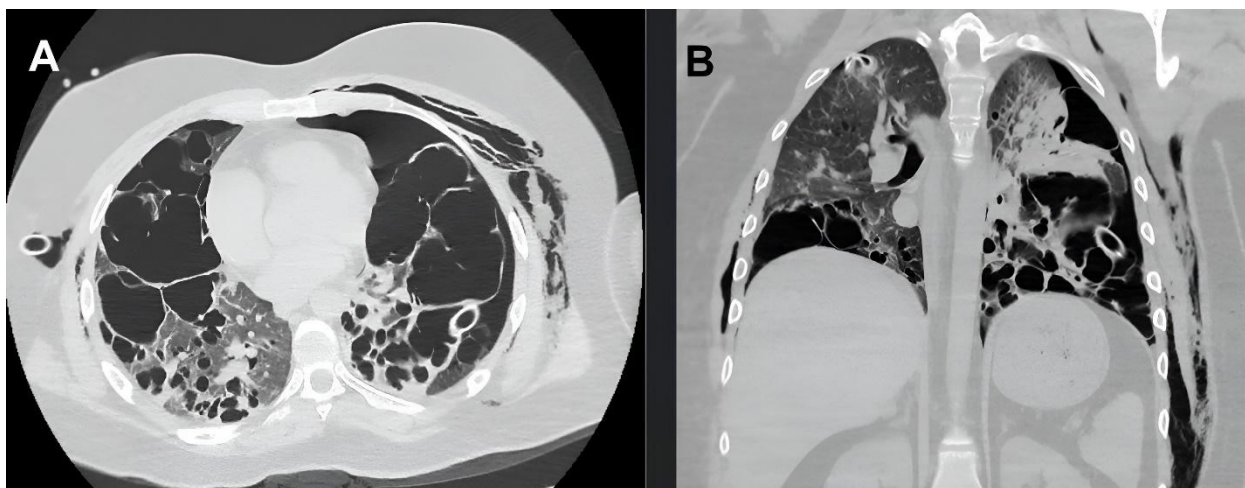


Figure 1. Chest CT scan.

(Panel C: Axial cut, Panel D: Coronal reconstruction): Progression of lung damage with coalescence of preexisting pulmonary cysts, presence of bilateral pneumothorax, more pronounced in the right hemithorax, with partial collapse of both lungs, and bilateral chest tube placement for pneumothorax management.

DISCUSSION

Cystic lung diseases represent a broad group of conditions characterized by cystic lesions in the lung parenchyma. Pulmonary cysts, defined as thin-walled cavities lined by epithelium or fibrous tissue, are differentiated from bullae and cavities using high-resolution computed tomography (HRCT), which is essential for evaluating the distribution and characteristics of these lesions. In this case, the findings of pulmonary cysts in a young patient with no prior lung disease or significant environmental exposure, but with a history of intensive vaping, suggest a mechanism of chronic lung injury potentially mediated by inhaled components of electronic cigarettes⁶.

The differential diagnosis of young patients with pulmonary cysts is complex. Pulmonary Langerhans cell histiocytosis, a disease associated with smoking, was a possible consideration; however, the absence of characteristic nodules and limited tobacco exposure made it less likely in this case. Lymphangiomyomatosis (LAM), though more common in women and associated with tuberous sclerosis, was included in the differential diagnosis. Excluding this pathology in men is challenging in sporadic cases; however, the absence of extrapulmonary manifestations, such as renal angiomyolipomas, made this diagnosis improbable⁷.

The bilateral spontaneous pneumothorax in this patient highlights the severity of potential complications in cystic diseases. The rupture of subpleural cysts, as observed in this case, is a frequent cause of pneumothorax in patients with advanced lung damage and represents a severe clinical outcome that can lead to respiratory failure and the need for mechanical ventilation, as occurred in our patient⁸. This case also underscores the importance of diagnostic limitations, as alpha-1 antitrypsin levels and SERPINA1 sequencing were not performed to exclude alpha-1 antitrypsin deficiency, a

rare but relevant cause of cystic lung disease in young individuals⁹.

Recent reports suggest that vaping may be associated with chronic structural changes in lung tissue, similar to those observed in cystic diseases, raising the need for a broader evaluation of these devices. Chronic exposure to compounds such as vitamin E acetate, diacetyl, and other aldehydes could mediate tissue damage mechanisms leading to cyst development and structural fragility of the lung parenchyma^{3,4}. Therefore, this case highlights the importance of critically evaluating the relationship between vaping and chronic lung damage, as well as the need for timely preventive and diagnostic strategies.

CONCLUSIONS

This case illustrates the potential for chronic lung damage and severe complications in young patients with a history of intensive vaping. The development of pulmonary cysts associated with prolonged exposure to electronic cigarettes underscores the importance of considering vaping as a risk factor for chronic lung diseases. Additionally, it emphasizes the need for further studies on the long-term effects of these devices and their relationship with cystic pulmonary manifestations, contributing to understanding the risks and regulations of vaping in the general population.

REFERENCES

1. Barrera-Núñez DA, López-Olmedo N, Zavala-Arciniega L, Barrientos-Gutiérrez I, Reynales-Shigematsu LM. Consumo de tabaco y uso de cigarro electrónico en adolescentes y adultos mexicanos. *Ensanut Continua* 2022. *Salud Publica Mex*

Pulmonary Cysts and Spontaneous Pneumothorax in a Young Vaper with Fatal Outcome: Case Report and Literature Review

- <https://doi.org/10.21149/14830>.<https://www.saludpublica.mx/index.php/spm/article/view/14830>
- II. Soto B, Costanzo L, Puskoor A, Akkari N, Geraghty P. The implications of Vitamin E acetate in E-cigarette, or vaping, product use-associated lung injury. *Ann Thorac Med*. 2023 Jan-Mar;18(1):1-9. DOI: 10.4103/atm.atm_144_22
- III. Alexander LEC, Bellinghausen AL, Eakin MN. What are the mechanisms underlying vaping-induced lung injury? *J Clin Invest*. 2020;130(6):2754-2756. <https://doi.org/10.1172/JCI138644>
<https://pmc.ncbi.nlm.nih.gov/articles/PMC10034821/>
- IV. Alitter Q, Jarrar A, Alsoud F, Gadelmoula I. Vaping and Cystic Lung Disease: An Underrecognized Relationship (abstract). *Am J Respir Crit Care Med*. 2023;207. https://doi.org/10.1164/ajrccm-conference.2023.207.1_MeetingAbstracts.A6673
https://www.atsjournals.org/doi/10.1164/ajrccm-conference.2023.207.1_MeetingAbstracts.A6673
- V. Damani J. Marijuana-associated cystic lung disease. *Chest*. 2021 Oct;160(4 Suppl). doi: 10.1016/j.chest.2021.07.1075. [https://journal.chestnet.org/article/S0012-3692\(21\)02526-5/fulltext](https://journal.chestnet.org/article/S0012-3692(21)02526-5/fulltext)
- VI. Lee KC, Kang EY, Yong HS, Kim C, Lee KY, Hwang SH, Oh YW. A Stepwise Diagnostic Approach to Cystic Lung Diseases for Radiologists. *Korean J Radiol*. 2019 Sep;20(9):1368-1380. <https://doi.org/10.3348/kjr.2019.0057>
<https://www.kjronline.org/DOIx.php?id=10.3348/kjr.2019.0057>
- VII. Cabeza Martínez B, Giménez Palleiro A, Mazzini Florindez SP. Enfermedades quísticas pulmonares. *Radiología*. 2022;64(Suppl 3):265-276. doi: 10.1016/j.rx.2022.09.008. <https://www.sciencedirect.com/science/article/abs/pii/S0033833822002247>
- VIII. Cooley J, Lee YCG, Gupta N. Spontaneous pneumothorax in diffuse cystic lung diseases. *Curr Opin Pulm Med*. 2017 Jul;23(4):323-333. doi: 10.1097/MCP.0000000000000391. <https://pmc.ncbi.nlm.nih.gov/articles/PMC5563542>
- IX. Fazleen A, Abbas A, Dunbar J, Welham B, Kong A, Wilkinson T. Alpha-Antitrypsin Deficiency as a cystic lung disease. *Eur Respir J*. 2023;62(suppl 67). doi: 10.1183/13993003.congress-2023.PA2413. <https://publications.ersnet.org/content/erj/62/suppl67/pa2413>