

Le Fort I-II Fracture Management: Case Based Literature Review

Grace Claudia¹, Putu Trisna Utami²

¹ Medical Doctor, Faculty of Medicine Udayana University, Denpasar, Bali, Indonesia

² Plastic Surgeon, Department of Plastic Reconstructive and Aesthetic Surgery, Bali Mandara General Hospital, Denpasar, Bali, Indonesia

ABSTRACT

Introduction: Midfacial fractures are among the most severe injuries encountered in emergency settings due to the risk of functional impairment and facial deformities. The Le Fort classification remains the most commonly used system for categorizing these fractures. Treating Le Fort II fractures is particularly complex due to the involvement of the orbital and nasal bones, along with the critical need to restore proper occlusion. Achieving pre-trauma occlusion is often the most difficult aspect of treating facial fractures.

Case Presentation: This study reported a 28-year-old Asian male was brought to the Emergency Room of Bali Mandara General Hospital by a bystander following a motorcycle accident in which he struck a pedestrian. He was diagnosed with Le Fort I-II and a right orbital floor fracture. The patient underwent surgery, including open reduction and internal fixation using miniplates and screws. The procedure successfully restored the patient's occlusion, and no reported postoperative complications.

Discussion: The diagnosis of Le Fort fractures is based on patient history, physical examination, and imaging studies. Identifying a pterygoid fracture is essential for diagnosing all types of Le Fort fractures. Prompt definitive treatment is critical to prevent long-term facial deformities.

Conclusion: Achieving proper occlusion is a marker of accurate alignment in managing facial fractures. Emphasizing functional restoration and deformity prevention significantly improves patient recovery and results.

KEYWORDS: Le Fort I, Le Fort II, malocclusion, midfacial, surgery

ARTICLE DETAILS

Published On:
13 December 2024

Available on:
<https://ijmscr.org/>

INTRODUCTION

Midfacial fractures include fractures of the maxilla, zygoma, and naso-orbito-ethmoid (NOE) complex. These fractures are classified into Le Fort I, Le Fort II, Le Fort III, zygomaticomaxillary (ZMC) complex fractures, zygomatic arch fractures, and NOE fractures.¹ Facial bones have both vertical and horizontal buttresses.²

Le Fort I is also called a Guerin fracture or low-level fracture, which often results from a horizontal force directed at the upper teeth.^{1,2,3} Le Fort I fractures cause disruption to the inferior part of the lateral and medial maxillary buttresses.⁴ Le Fort II fractures, also known as pyramidal or sub-zygomatic fractures, often occur due to a superiorly directed force that separates the maxilla and nasal complex from the orbital and zygomatic structures. Le Fort II fractures cause disruption of the medial maxillary buttress and divide

the pterygoid laminae approximately halfway up. They affect the lateral, upper transverse, and posterior maxillary buttresses, leading to discontinuity of the inferomedial orbital

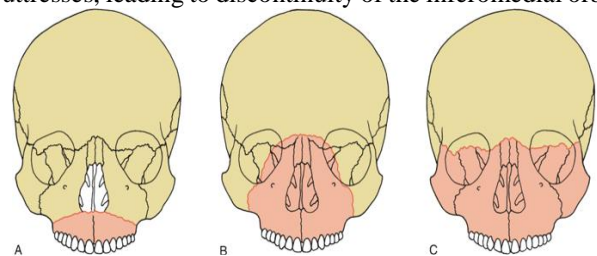


Figure 1. (A) Le Fort I, (B) Le Fort II, (C) Le Fort III¹

rim.^{2,5} Le Fort III fractures, also referred to as transverse fractures, craniofacial disjunctions, or supra-zygomatic fractures, result from a higher-positioned

Le Fort I-II Fracture Management: Case Based Literature Review

horizontal force, such as at the upper edges of the maxilla, which separates the face from the skull base.^{1,2,3} A combination of Le Fort I, II, and III fractures can occur on both sides of the face.⁶

CASE PRESENTATION

A 28-year-old Asian male was brought to the Emergency Room of Bali Mandara General Hospital by a bystander following a motorcycle accident in which he struck a pedestrian. The patient arrived conscious with extensive facial edema. He had no significant medical history, no relevant family history, and no known drug or psychological history.

After systemic evaluation and stabilization, the patient underwent laboratory and imaging tests. The initial maxillofacial physical examination revealed facial edema, predominantly on the right side, bilateral periorbital ecchymosis, double vision when looking to the right, a floating maxilla, open-bite malocclusion, reduced malar eminence, tenderness in the right and left maxilla, crepitation and tenderness in the right zygoma and nasal region, bilateral epistaxis, septal deviation, intraoral excoriation, and difficulty in evaluating the tonsils and pharynx. Upon examination of the CT scan, fractures were detected in the anterior, lateral, and medial walls of the bilateral maxillary sinuses, as well as fractures of the bilateral pterygoid, nasal bone, left sphenoid wing, and right orbital floor. Bilateral maxillary and ethmoidal sinus fractures were also observed, along with soft tissue swelling in the bilateral maxillary region and subcutaneous emphysema in the right maxilla. Based on the CT scan images, a diagnosis of Le Fort I-II fractures and a right orbital floor fracture was made.

The patient underwent surgery two days post-trauma, performed by a plastic surgeon. The procedure included maxillary reconstruction, open reduction, and internal fixation (ORIF) with miniplate screws, along with orbital floor exploration to treat the fractures. Empiric antibiotics were administered. The procedure was carried out under general anesthesia with orotracheal intubation. An arch bar was placed before the ORIF with miniplates and screws. To expose the fractures, an intraoral approach was made through an upper gingivobuccal sulcus incision, along with open-sky and subciliary lower eyelid incisions. The right orbital floor fracture was accessed through a right subciliary approach. Nasal elevation and repositioning were performed using Ash forceps and an open-sky approach, where a comminuted nasal dorsum fracture was found. Miniplates and screws were placed on the right and left nasal bones, and another miniplate and screw were placed on the orbital floor after the nasal fractures were fixed.

For the comminuted right maxilla and left maxilla fractures, the exposure was made through an upper gingivobuccal sulcus incision. Hematomas were removed from the right and left maxillary sinuses. The left maxilla was in better condition than the right, so it was fixed first. A

comminuted fracture fragment was found on the medial maxillary buttress, and the fracture fragment was assembled with a 2.0 mm miniplate and 6 mm screws and placed at the fracture site, connecting to the right inferior orbital rim. After completing the ORIF, the intraoral incision was closed with 3-0 absorbable sutures, while the subciliary and open-sky incisions were closed with 6-0 non-absorbable sutures. The procedure was finalized with nasal packing and followed by nasal splinting.

The patient received antibiotics, including Ceftriaxone 1 gram every 12 hours and Metronidazole 500 mg every 8 hours during hospitalization. Pain management was provided using a combination of Fentanyl (175 mg), Tramadol (150 mg), and Dexketoprofen (100 mg) diluted in 50 cc of normal saline, administered every 24 hours. Post-operative blood tests revealed leukocytosis at 14,790/ μ L with elevated neutrophil at 13,220/ μ L. The patient showed daily improvement and was advised to follow a soft diet for six weeks while maintaining strict oral hygiene to prevent infection. The patient was discharged from the hospital on the fourth day after surgery with good occlusion and no reported complications. Occlusion was monitored during follow-up visits.

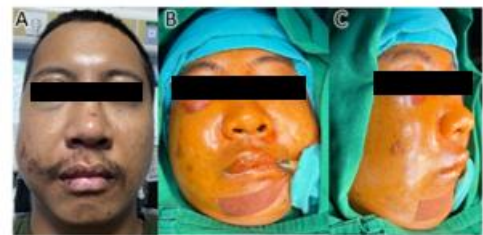

Figure 2. Clinical and pre-surgical appearance

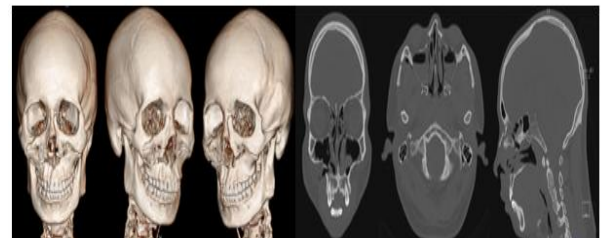


Figure 3. 3D-CT scan, coronal view, axial, and sagittal view

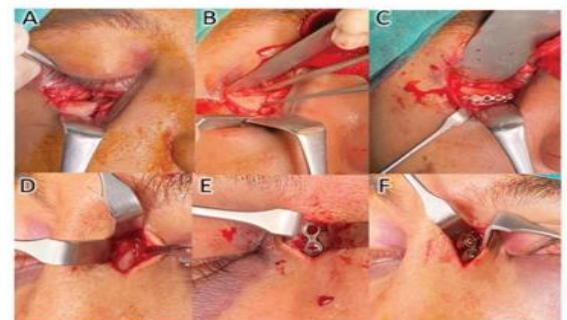


Figure 4. Intraoperative Views of the Surgical Step. (A) The right inferior orbital rim and orbital floor fracture, (B) fracture reposition and reduction, (C) 5-hole miniplate midface system 1.6mm was placed on zygomaticomaxillary suture, (D) nasal dorsal comminuted fracture, (E) 3-hole miniplate midface system 1.6mm was placed on the right nasal bone (4mm screw), (F) 4-hole miniplate midface system 1.6mm was placed on the left nasal bone. All fixation for orbital and nasal fracture were used 4mm screw.

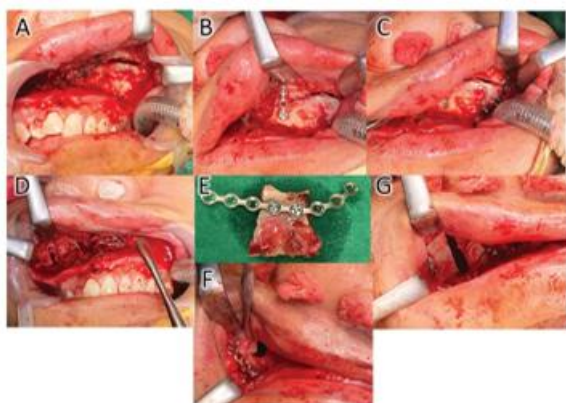


Figure 5. Intraoperative Views of the Surgical Step. (A) The left maxillary fracture, (B) 3-hole miniplate midface system 2.0mm was placed on medial buttress (6mm screw), (C) 5-hole miniplate midface system 2.0mm was placed on lateral buttress (6mm screw) of left maxilla. (D) The right maxillary fracture, (E) segmented bone, (F) 12-hole miniplate midface system 2.0mm was placed on lateral buttress (5mm and 6mm screw), (G) 8-hole miniplate midface system 2.0mm was placed on medial buttress (5mm screw) of right maxilla.

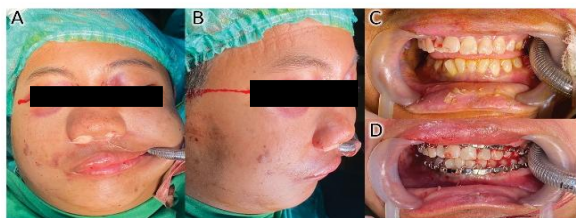


Figure 6. (A) Anterior and (B) lateral view of the patient, (C) Before (open bite and cross bite malocclusion), (D) After (good occlusion)

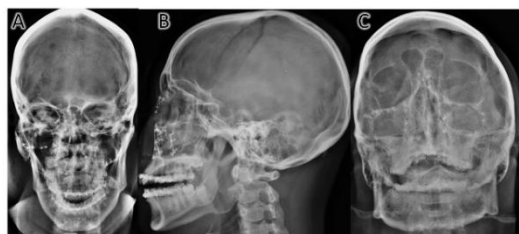

Figure 7. (A,B) Skull AP/lateral view and (C) Water's post-operative evaluation showed miniplate fixation on the inferior wall of the right orbit, the anteromedial and lateral walls of the right and left maxillary sinuses, and the nasal bone in good position.

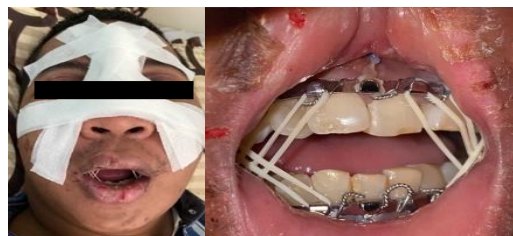

Figure 8. On the 3rd post-operative day (POD), the nasal packing was removed, and MMF (maxillomandibular fixation) rubber bands were applied, along with nasal splinting correction.

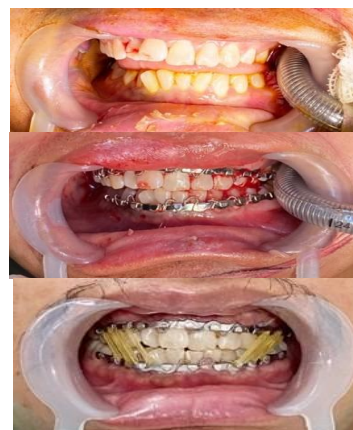

Figure 9. (top to bottom) Pre-operative (malocclusion with open-bite and cross-bite), post-operative day 0 (good occlusion), post-operative day 31 (good occlusion with MMF rubber bands applied)

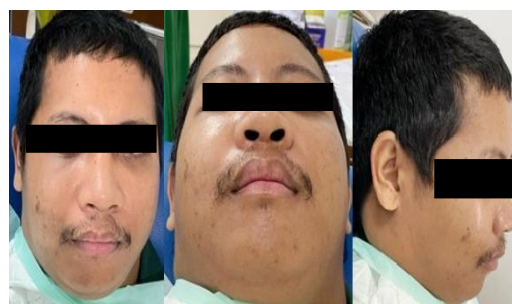

Figure 10. On the 31st POD, the patient progressed without complications and had good occlusion.

DISCUSSION

Maxillary fractures are most commonly caused by motor vehicle accidents compared to other causes.⁶ the evaluation of maxillofacial fractures occurs during the secondary survey, after stabilization in the primary survey. The clinical presentation varies depending on the type of Le Fort fracture present. The examination of the midface begins by assessing the mobility of the maxilla as an independent structure. Palpation and applying firm pressure to the midfacial region help detect bone contour deformities. A thorough evaluation of the nasal, paranasal, and intra-oral regions is also necessary. Additionally, a neurological assessment is required to evaluate cranial nerve function.¹ A CT scan is the gold standard for definitively diagnosing maxillary fractures, with coronal sections offering the best view of suspected orbital floor fractures. The diagnosis of a Le Fort fracture is based on the patient's history, physical examination, and imaging studies.^{2,6}

Patient was examined according to Advanced Trauma Life Support (ATLS) principles of primary survey. The fracture line of this patient extended through the lateral antral wall, lateral nasal wall, lower third of the septum, and crossed to the nasofrontal suture through the nasal bone along the maxilla, into the inferior medial orbit, and the right orbital floor to the zygomaticomaxillary suture and both pterygoid laminae. The patient's presentation fits the criteria for Le Fort I and II fractures. Pterygoid fractures are present in all types of Le Fort fractures and are crucial for establishing the

Le Fort I-II Fracture Management: Case Based Literature Review

diagnosis. However, these fractures are not exclusive to Le Fort fractures.⁷ A 5-year study by Garg RK et al. in 2015 revealed that among 209 patients with pterygoid fractures due to craniofacial trauma, 78 patients (37.3%) had fractures that were not associated to Le Fort fractures.⁸

An epidemiological study conducted in Rome over a 10-year period found that Le Fort fractures were relatively rare, with only 18 patients (1.8%) out of 1,007 facial fracture cases.⁹ Similarly, a study in South America involving 754 patients with facial fractures reported that 50 patients (6.6%) had Le Fort fractures. Mixed Le Fort types were found in only 10 cases, including 3 cases of Le Fort I-II and 7 cases of Le Fort II-III, with no instances of Le Fort I-III.¹⁰

A study by Xiao-Dong et al. reported that out of 241 patients (29%) with maxillary fractures, there were 32 cases of Le Fort I fractures (2.15%), 59 cases of Le Fort II fractures (4.64%), 28 cases of Le Fort III fractures (1.88%), and 122 cases (8.21%) involving other types of fractures.¹¹ Similarly, Dargani et al.'s study found an average of 15.2 Le Fort fracture cases per year, making up 9.23% of all maxillofacial pathologies and accounting for 24.84% of maxillofacial trauma cases treated in their department. The majority of cases (90%) involved males, with most patients being between 21-30 years old.¹²

The management of maxillary fractures typically involves direct exposure of the fracture, manual reduction, and reconstruction of the facial buttresses to prevent elongation or flattening of the face. Autogenous bone grafts may be used if the bone is severely damaged. The main goals are to restore pre-injury occlusion, normal chewing function, and the midfacial contour and projection. Proper occlusion is key to ensuring correct alignment. Maxillary fractures generally displace backward and downward, reduction must be performed forward and upward. Stabilizing the maxilla in relation to the surrounding facial structures is crucial.²

Historically, midface fractures were managed through either open or closed reduction methods. However, recent studies show that open reduction paired with miniplate and screw fixation provides superior access to fracture sites and improve bone contouring during surgery. This method has become the preferred standard, providing improved functional and cosmetic outcomes. While older methods relied on various wiring techniques, current treatments prioritize rigid internal fixation using plates and screws for greater stability and effectiveness.^{1,6}

Prompt and definitive treatment of maxillary fractures is essential to prevent facial deformities. Delaying fracture management for several weeks after trauma often necessitates a full open reduction due to partial healing. In cases of maxillary fractures, an intact mandible can help reduce the risk of facial elongation and retrusion. A common complication following Le Fort fracture reconstruction is the reduction in midfacial projection and height.¹⁰ On the present case, surgery was performed two days after the trauma, following the guideline that ORIF (open reduction and

internal fixation) of the maxilla should be done as early as possible, preferably less than three weeks, to avoid deformities. Since fractures are rarely symmetrical, reconstruction usually starts on the side with less damage, as was done in this case.^{10,14}

Le Fort I fracture are generally accessed through an upper sulcus gingivobuccal incision, whereas Le Fort II fractures can be managed through subciliary or maxillary vestibular incisions, or by utilizing existing lacerations. In cases of Le Fort III fractures, a bicoronal incision, upper blepharoplasty, or existing lacerations may be necessary, particularly if a ZMC (zygomaticomaxillary complex) fracture is present.^{2,10,13} Nasal fractures are often addressed, using an open sky approach, which provide direct access to the fracture site. If nasal fractures cannot be managed with closed reduction, particularly if they occur alongside Le Fort or frontal bone fractures, a modified Lynch incision coupled with an upper gingivobuccal sulcus approach is typically favored for better access.

In this case, the upper gingivobuccal sulcus incision was used, as supported by research indicating that it enhances the visualization of the medial and lateral vertical buttresses. The plates were carefully placed in alignment with the direction of masticatory forces to ensure that the reconstruction was not compromised.^{10,15,16,17} Additionally, a coronal approach can provide wide exposure to the zygomatic arch, though this technique carries a higher risk of complications due to the dissection of neurovascular structures.⁵ Le Fort I fractures were fixed along the vertical maxillary buttress at the pyriform aperture and zygoma, while Le Fort II fractures were secured at the frontonasal suture, bilateral infraorbital rims, and zygomaticomaxillary buttresses.⁶ Intermaxillary fixation (IMF) can be released six weeks after occlusion is stabilized.¹⁶

Prophylactic systemic antibiotics were administered to prevent cheek cellulitis.⁷ Postoperative antibiotics were prescribed for 7 days, which aligns with Kochar et al.'s study suggesting that postoperative antibiotics can be given for 5 to 10 days depending on the fracture's exposure to external environments or communication with intraoral or intranasal spaces.¹⁷ Postoperative leukocytosis and elevated neutrophil levels were observed, likely reflecting the body's response to psychological or physiological stress, bleeding, or temporary bacteremia, rather than indicating infectious complications.¹⁹

CONCLUSION

The time of definitive management of maxillary fracture is done as early as possible to avoid facial deformities. Management of facial fracture with focus on reducing functional disruption and deformity will improve patient outcome. Achieving proper occlusion is a marker of accurate alignment in managing facial fractures. Emphasizing functional restoration and deformity prevention significantly improves patient recovery and results. Good

Le Fort I-II Fracture Management: Case Based Literature Review

cooperation between surgeon and patient is needed to support patient's recovery.

CONFLICT OF INTEREST There are no conflict of interest

DECLARATION OF PATIENT CONSENT

The authors confirm that informed consents (Consent to Participate and Consent to Publish) were obtained for this study.

DATA AVAILABILITY STATEMENT

The data generated during the current study are available from the corresponding author on reasonable request.

REFERENCES

- I. Hupp James R., et al. Contemporary Oral and Maxillofacial Surgery 7th edition. Elsevier. Philadelphia. 2019. 519-538
- II. Bonanthaya Krishnamurthy, Panneerselvam Elavenil, Kumar SMVV. Rai Anshul. Oral and Maxillofacial Surgery for the Clinician. India. 2021:1125-1145
- III. Moe KS et al. Maxillary and Le Fort Fracture. Medscape.2020.
<https://emedicine.medscape.com/article/1283568-overview#a>
- IV. Hopper RA., Salemy S., Sze RW. "Diagnosis of Midface Fractures with CT: What the Surgeon Needs to Know." Radiographics. 2006. 26(3): 783-793.
- V. Phillips BJ, Turco LM. Le Fort Fractures: A Collective Review. Bull Emerg Trauma. USA. 2017;5(4):221-230.
- VI. Miloro, M., Ghali, G. E., Larsen, P., dan Waite, P., 2011, Peterson's Principles of Oral and Maxillofacial Surgery, 3rd ed., PMPH-USA, Suite, pp. 455-463.
- VII. Kim Hak Su, Kim Seong Eun et al. Management of Le Fort I fracture. Arch Craniofac Surg. Korea. 2017:Vol.18 No.1,5-8
- VIII. Garg RK, Alsheik NH, Afifi AM, Gentry LR. Pterygoid plate fractures: not limited to Le Fort fractures. J Craniofac Surg 2015;26:1823-5.
- IX. Juncar *et al.* An epidemiological analysis of maxillofacial fractures: a 10-year cross-sectional cohort retrospective study of 1007 patients. Romania. *BMC Oral Health* (2021) 21:128
- X. Campos GH, Leandro L, Yamamoto MK, Júnior RC, Luz JGC. Trends in Le Fort Fractures at a South American Trauma Care Center: Characteristics and Management. *J Maxillofac Oral Surg.* 2016 Mar; 15(1):32-7.
- XI. Xiao-Dong L, Qiu-Xu W, Wei-Xian L. Epidemiological pattern of maxillofacial fractures in northern China: A retrospective study of 829 cases. *Medicine (Baltimore).* 2020; 99(9):e19299. doi:10.1097/MD.00000000000019299
- XII. Dargani Michel Fabien, Bissa Haréfétéguéna, Millogo Mathieu, Idani Motandi, Essobiyou Tamassi Bertrand, Konsem Tarcissus, Epidemiology and management of Lefort fractures at the Sylvanus Olympio University Hospital of Lomé (Togo), *Advances in Oral and Maxillofacial Surgery*, Volume 8, 2022, 100376, ISSN 2667-1476,
<https://doi.org/10.1016/j.adoms.2022.100376>.
- XIII. McRae M, Frodel J. Midface Fractures. *Facial Plastic Surgery.* New York. 2000;Vol.16(2)
- XIV. Bell RB, Dierks EJ, Homer L, Potter BE. Management of cerebrospinal fluid leak associated with craniomaxillofacial trauma. *J Oral Maxillofac Surg* 2004 Jun; 62 (6):676–84.
- XV. Wang Weitao, Lee Thomas, Ducic Yadranko. Nasal Fractures: The Role of Primary Reduction and Secondary Revision. *Facial Plast Surgery.* New York. 2019; 35:590–601.
- XVI. Louis M., Agrawal N., Midface fractures II, *Semin. Plast. Surg.* 31 (2017) 94–99.
- XVII. Kochhar A, Byrne PJ. Surgical management of complex midfacial fractures. *Otolaryngol Clin North Am* 2013; 46:759-78.
- XVIII. Manson PN. Facial fractures. In: Mathes SJ, Hentz VR, editors. *Plastic surgery.* Vol. VIII. Philadelphia, PA: Saunders Elsevier; 2006. p. 229-55.
- XIX. Cohen B, Dery E, Cattan A, Matot I. Is leukocytosis a common finding in the postoperative period? A3067. In *The anesthesiology Annual Meeting* 2013.