

## Hepatic Vein Thrombosis Secondary to Protein C and S Deficiency

Anilkumar Biradar<sup>1</sup>, Shankarappa R S<sup>2</sup>

<sup>1</sup>Resident, Department of General Medicine, Sri Siddhartha Medical College Hospital and Research Centre, Tumakuru, Karnataka

<sup>2</sup>Professor, Department of General Medicine, Sri Siddhartha Medical College Hospital and Research Centre, Tumakuru, Karnataka

### ABSTRACT

Hepatic Venous Outflow Tract Obstruction is obstruction of the hepatic venous outflow tract can be primary due to obstruction by thrombosis or secondary due to compression of hepatic vein, inferior vena cava or both. Causes being prothrombotic inherited or acquired. Classical clinical triad being abdominal pain, ascites, and tender hepatomegaly. Ultrasound, Computed Tomography or Magnetic Resonance Imaging of abdomen are required for confirmation. Long-term anticoagulation with vitamin K antagonists should be started. 24year female with abdominal distention and pain, having pallor, fluid distended abdomen. CT abdomen revealed an hypodense focal lesion in right lobe, ascites with Hepatic Vein Thrombosis. Haematology Low Functional antithrombin activity of 29 units, low Free Protein S Antigen of 42.8 units, very low Protein C functional activity of 16.5 units was observed. Frequency of prothrombotic hepatic venous outflow tract obstruction in India is more compared to west. So considered in all cases with acute, chronic liver disease with complications.

**KEYWORDS:** Hepatic Venous Outflow Tract Obstruction, Protein C deficiency, Protein S deficiency, Antithrombin activity

### ARTICLE DETAILS

**Published On:**  
**28 November 2024**

**Available on:**  
**<https://ijmscr.org/>**

### INTRODUCTION

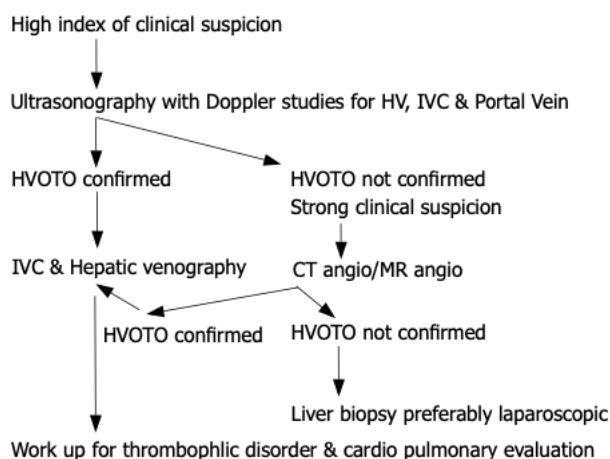
Hepatic Venous Outflow Tract Obstruction or Budd-Chiari Syndrome is defined as obstruction of the hepatic venous outflow tract anywhere from the small hepatic venules to the entrance of inferior vena cava into the right atrium. This condition encompasses hepatic vein thrombosis and obliterative hepatocavopathy.<sup>1</sup> It can be primary or secondary, primary involves thrombosis in the absence of a known cause and secondary refers to obstruction of the hepatic outflow due to compression by a space occupying lesion like liver abscess, cyst or invasion by a malignancy. Common causes being prothrombotic conditions which may be inherited like Antithrombin 3 deficiency, Protein C deficiency, Protein S deficiency, Factor V Leiden mutation or acquired like Oral contraceptives, Myeloproliferative disorders, Antiphospholipid syndrome, Paroxysmal nocturnal haemoglobinuria, Infections Liver abscess, Hydatid cyst, Aspergillosis, Tuberculosis, Malignancies Adrenal carcinoma, Hepatocellular carcinoma, Leukaemia and miscellaneous causes being Bechet's disease, Inflammatory Bowel Disease, Sarcoidosis, Polycystic liver disease, Trauma. It can involve hepatic vein, inferior vena cava or both. Microscopic features being sinusoidal dilation,

centrilobular congestion, stasis and ischemia leading to hepatocyte loss and parenchymal extinction resulting in liver dysfunction leading to venocentric cirrhosis because of fibrosis bridging together central areas. Benign regenerative nodules are common due to increased arterial inflow to certain areas and may be difficult to differentiate from malignancy on imaging.<sup>2</sup> Clinical manifestations are heterogeneous varying from completely asymptomatic patients up to 20% to acute liver failure. Clinically may present with symptom of fever and examination findings include pedal edema, truncal veins, presence of back veins with below-upward flow and the absence of abdominojugular reflux which are suggestive of Inferior venacaval obstruction. The classical clinical triad being abdominal pain, ascites, and tender hepatomegaly.<sup>3</sup> It may present with complications of chronic liver disease including Variceal bleeding, Hepatic encephalopathy, Hepatorenal Syndrome, and Hepatocellular carcinoma. Hence Budd Chiai Syndrome should be considered in all asymptomatic or symptomatic patients with acute or chronic liver disease. Diagnostic evaluation include complete blood count, liver function tests, renal function tests, imaging studies like Doppler ultrasound is the first-line investigation, Computed Tomography or Magnetic

## Hepatic Vein Thrombosis Secondary to Protein C and S Deficiency

Resonance Imaging for confirmation and venography is restricted to cases of diagnostic uncertainty or for better anatomic characterization prior to interventional therapy and Ascitic fluid analysis. Liver biopsy is rarely required for diagnosis. Diagnostic workup should also include search for an underlying cause, including prothrombotic conditions and local causes such as malignancies and intra-abdominal inflammatory conditions. Identification of one risk factor should not deter the search for additional risk factors as multiple risk factors may be present. Testing for JAK2V617F mutation in peripheral blood is the first step in the diagnosis of myeloproliferative neoplasms. If negative calreticulin mutation testing should be done. Bone marrow biopsy should be considered in those negative for both these biomarkers, irrespective of peripheral blood counts. Long-term anticoagulation with vitamin K antagonists after an initial overlap with low molecular weight heparin should be started in all asymptomatic and symptomatic patients with a target prothrombin time and international normalized ratio in the range of 2 to 3. Complications of portal hypertension when adequately treated do not contraindicate anticoagulation. However anticoagulants should be withheld prior to any Figure 1 Evaluation of patient with Budd-Chiari Syndrome<sup>4</sup>

invasive procedure. It may also be prudent to delay anticoagulation till high risk varices have been adequately tackled. Angioplasty or stenting is an appropriate decompressive therapy in patients with short segment Hepatic vein or Inferior Venacava stenosis. Patients who do not respond or deteriorate on initial therapy should be considered for portal diversion techniques including Trans jugular Intrahepatic Portosystemic Shunt and surgical shunts such as Mesocaval, Mesoatrial, Portocaval, Cavo atrial shunts. Trans jugular Intrahepatic Portosystemic Shunt is preferred over surgical shunts because of lower mortality and morbidity. Polytetrafluorethylene covered stents reduces the occurrence of post TIPS shunt obstruction or dysfunction. However Trans jugular Intrahepatic Portosystemic Shunt may be technically challenging in the setting of Budd Chiari syndrome and a transcaval approach direct puncture from intrahepatic IVC may be required in almost 50% cases due to complete occlusion of all the three Hepatic veins<sup>1</sup>. Liver transplantation is indicated in patients with fulminant hepatic failure and as salvage therapy when portal diversion techniques fail or are not feasible. Therapy for the underlying disease should be simultaneously initiated.



### CASE REPORT

A female aged 24 years presented to Medicine outpatient at Sri Siddhartha Medical College Tumakuru Karnataka with abdominal distention of 1 week duration insidious onset, gradually progressive associated with nausea and upper abdominal pain of 3 days duration sudden onset, non-progressive, dull aching, non-radiating without any aggravating or relieving factors and no significant past history or family history of any liver or autoimmune disorders. On examination patient conscious cooperative moderately built and nourished with presence of pallor and absence of icterus, cyanosis, clubbing, significant lymphadenopathy and edema. On systemic examination abdomen is uniformly distended with fullness of flanks, transversely stretched and everted umbilicus, tenderness in right hypochondrium and epigastric area without any organomegaly and with clinical evidence of free fluid in the

peritoneum with positive horse shoe shaped dullness and positive shifting dullness. Routine investigations revealed Leucocytosis of  $15.76 \times 10^3/\text{mm}^3$ , Haemoglobin of 13.4 g/dl, Platelets of 2.80 lakhs/ $\text{mm}^3$ , MCH 25pg, MCV 78.7fL, Hyperbilirubinemia of 2.0mg/dl with Direct bilirubin 0.7mg/dl, Indirect bilirubin 1.3mg/dl, Elevated hepatic enzymes SGOT 750U/L (14-36 U/L), SGPT 536U/L (<35U/L), Serum total protein 6.7gm/dl, Hypoalbuminemia of 2.9gm/dl, Serum globulin 3.7gm/dl with reduced A/G ratio of 0.78, hypercoagulopathy with prolonged prothrombin time of 33.4 seconds (10-16 seconds), INR of 2.8. Normal Serum values of sodium 135mmol/l, potassium 4.6 mmol/l, urea 30mg/dl, creatinine 1.4mg/dl, Lipase and Amylase. Serum markers HBsAg, HCV, HIV are non-reactive. Ascitic fluid was pale yellow with cell count of 600 on microscopy with predominant neutrophil 60% and lymphocytes 40%, mesothelial cells and reactive mesothelial

## Hepatic Vein Thrombosis Secondary to Protein C and S Deficiency

cells in proteinaceous background. On ultrasound abdomen there was diffuse increase in liver parenchymal echotexture and increase in periportal echotexture with gross ascites. Contrast enhanced Computed Tomography abdomen revealed an ill-defined hypodense focal lesion in right lobe of liver, moderate ascites with Hepatic Vein Thrombosis. Haematology report from Victoria Hospital Bangalore revealed low Functional antithrombin activity of 29 units (76-128 units), low Free Protein S Antigen of 42.8 units (60.1-113.6units ), very low Protein C functional activity of 16.5 units (83-168units) and negative for Molecular biology PCR for JAK(V617F) mutation.

### DISCUSSION

Frequency of inherited and acquired prothrombotic in hepatic venous outflow tract obstruction in India is more compared to western countries, Protein C deficiency in India is 12.7% compared to 12.5%, Protein S deficiency in India is 6.4% compared to 2.7%, Antithrombin deficiency in India is 1.8% compared to 0% in west.<sup>1</sup> Incidence of Budd Chiari Syndrome in India is 6.8 to 12 per 1,00,000 population.<sup>5</sup> Simultaneous presence of two hereditary coagulation disorders can lead to multiple venous thromboses and recurrent ischemic stroke. An appealing therapeutic option in poorly compliant patients with these two hereditary clotting defects is the replacement of long-term anticoagulation with a vitamin K antagonist by a direct oral anticoagulant.<sup>6</sup> Abdominal pain, hepatomegaly, and ascites were common in Budd Chiari Syndrome, whereas splenomegaly and gastrointestinal bleeding were the major manifestations of Portal vein thrombosis. In Portal vein thrombosis, the most common inherited risk factor was protein C deficiency followed by protein S deficiency and factor V Leiden mutation. Inherited prothrombotic defects were detected in a significant number of patients with Budd Chiari Syndrome and Portal vein thrombosis. The prevalence of protein C deficiency in Budd Chiari Syndrome and Portal vein thrombosis was comparable to the prevalence found in previous Indian and Western studies.<sup>3</sup>

### CONCLUSION

Due to its low incidence Budd Chiari Syndrome, Hepatic Venous Outflow Tract obstruction is difficult to detect in clinical practice. Most common cause of portal hypertension is cirrhosis of liver, Hepatic Venous Outflow Tract obstruction should be considered in all asymptomatic or symptomatic patients with acute, chronic liver disease, complications of chronic liver disease. Complete evaluation of suspected Budd Chiari syndrome is needed as inherited prothrombotic defects are more important than acquired predisposing factors.<sup>3</sup> Future Indian studies are required to elucidate the genetic basis of protein C and S deficiencies and optimize therapeutic outcomes in BCS management. The integration of genetic testing and minimally invasive interventions holds promise for improving prognosis.

### REFERENCES

- I. Arka De, Yogesh K Chawla. API Textbook of Medicine. HVOTO, EHPVO and NCPF 12<sup>th</sup> edition. New Delhi:2022. Vol 2. Chapter 8, P.1615-1617.
- II. Friedman LS. Harrison's Principles of Internal Medicine Textbook. Abdominal swelling and Ascites 21st edition. New York: McGraw-Hill Education; 2022. Vol 1.chapter 50, p. 323.
- III. Bhattacharyya M, Makharia G, Kannan M, Ahmed RP, Gupta PK, Saxena R. Inherited prothrombotic defects in Budd-Chiari syndrome and portal vein thrombosis: a study from North India. *Am J Clin Pathol.* 2004 Jun;121(6):844-7
- IV. Amarapurkar DN, Punamiya SJ, Patel ND. Changing spectrum of Budd-Chiari syndrome in India with special reference to non-surgical treatment. *World J Gastroenterol* 2008; 14(2):278-285.
- V. Mancuso A. An update on management of Budd-Chiari syndrome. *Ann Hepatol.* 2014 May-Jun;13(3):323-6. PMID: 24756006.
- VI. Finsterer J. Hereditary Protein S Deficiency and Activated Protein C Resistance Manifesting With Recurrent Thrombosis and Stroke. *Cureus.* 2023 Jan 20;15(1):e34012. doi: 10.7759/cureus.34012. PMID: 36824536; PMCID: PMC9941041.