

## An Analysis of Flaps in Reconstructive Surgery

**Pablo Alberto Mendoza Sánchez<sup>1</sup>, Francisco Alberto Montaña Vasquez<sup>2</sup>, Marco Antonio Cruz López<sup>3</sup>, Juan Jesús Ortega Landeros<sup>4</sup>, Ezequiel Ignacio Salcedo Ayala<sup>5</sup>, Jose Manuel Gómez Pérez<sup>6</sup>, Roberto Alejandro Ruiz Velasco Cisneros<sup>7</sup>, Erick Hidrogo Ordaz<sup>8</sup>, Iberia María Ossa Nájera<sup>9</sup>**

<sup>1</sup>Hospital General Dr Miguel Silva.

<sup>2</sup>Hospital General Regional Imss Ii

<sup>3</sup>Issste Hospital General Dra. Columba Rivera Osorio. "Centro De Estudio E Investigación En Enfermedades Hepáticas Y Toxicológicas".

<sup>4</sup>Hospital Regional Licenciado Adolfo López Mateos Issste Cmdx

<sup>5</sup>Issste Hospital General Dr Francisco Galindo Chávez

<sup>6</sup>Hospital Regional De Alta Especialidad Gustavo A. Rovirosa Pérez

<sup>7</sup>Umae Centro Médico Nacional De Occidente

<sup>8</sup>Issste Hospital General Dr Francisco Galindo Chávez

<sup>9</sup>Hospital General Reynosa "Dr. José Ma. Cantú Garza

### ABSTRACT

This literature review article will provide a comprehensive analysis of flaps in reconstructive surgery, specifically discussing their description, indications, problems, and treatment. This study will investigate the epidemiology of flaps and their clinical importance. This text will address the procedures employed in the application of flaps, emphasizing the significance of preoperative planning and surgical approaches. Furthermore, this text will delve into the intricacies linked to flaps and provide a thorough analysis of the benefits and difficulties involved with their utilization in reconstructive surgery. A summary highlighting the essential elements of this evaluation will be presented.

### ARTICLE DETAILS

**Published On:**  
**29 June 2024**

**Available on:**  
**<https://ijmscr.org/>**

### INTRODUCTION

In recent decades, reconstructive surgery has made substantial advancements, with flaps becoming a crucial technique for repairing soft tissue deformities. These techniques enable the transplantation of healthy vascularized tissue from one part of the body to another, with the aim of restoring the physical structure, functionality, and visual appearance. Flaps have gained significant popularity as a procedure in several medical specialties such as plastic surgery, oncological surgery, and traumatology.

The decision to employ flaps in reconstructive surgery is founded upon the necessity to reinstate tissue integrity and enhance the quality of life for patients. These techniques are particularly applicable in instances of extensive skin abnormalities, tissue loss resulting from surgical resections or trauma, and post-mastectomy breast reconstruction, among other scenarios. Flaps are a highly successful method for repairing soft tissues by providing a vascularized basis that guarantees their survival at the recipient location.

Effective execution of flaps necessitates meticulous preparation, specific surgical expertise, and a multidisciplinary methodology. The selection of the appropriate flap type is determined by several parameters, including the precise position and dimensions of the defect, the presence of nearby tissue that may be used, and the level of vascularization needed. Furthermore, a profound understanding of area anatomy, as well as expertise in microsurgery and vascular anastomosis procedures, is essential for attaining the best possible outcomes.

The purpose of this review article is to offer a comprehensive examination of flaps in reconstructive surgery, including their description, indications, problems, and proper management. Furthermore, this text will examine the benefits and difficulties linked to its utilization, and will also showcase the latest developments in the sector. An all-encompassing approach to these matters will empower healthcare practitioners to make well-informed judgments on the selection and implementation of flaps in reconstructive

## An Analysis of Flaps in Reconstructive Surgery

surgery, therefore enhancing results and maximizing patient care and contentment.

In the realm of reconstructive surgery, flaps refer to sections of tissue that are relocated from one area of the body to another in order to hide or substitute soft tissue imperfections. The flaps can vary in type, depending on their source and blood supply. Local flaps are derived from tissue that is located next to the area of damage, whereas regional flaps are obtained from a nearby region in proximity to the damaged location. In contrast, free flaps include the transplantation of

tissue from a remote area, along with a microsurgical vascular anastomosis to ensure continuous blood circulation.

The selection of the flap kind is contingent upon the dimensions, placement, and intricacy of the defect, in addition to the expertise and inclinations of the surgeon. Furthermore, flaps can be categorized according on their structure, such as island flaps that retain a vascular pedicle connecting the flap to its point of origin, and compound flaps that consist of many tissues, such as skin and muscle tissue.

### Mathes and Nahai Classification of Muscle Flaps

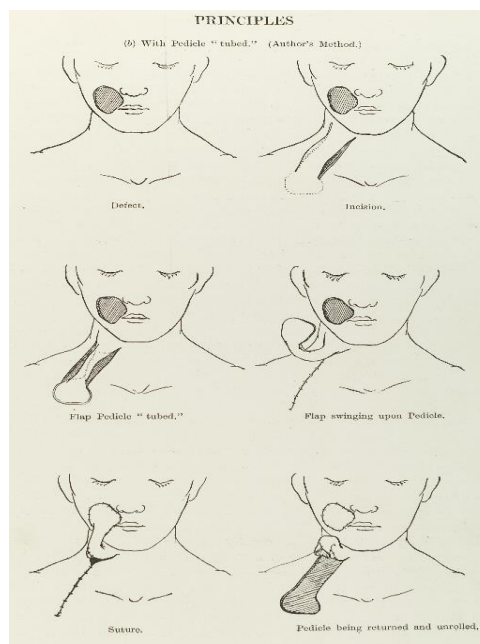
Type	Blood Supply Characteristics	Examples	Indications
Type I	<b>Single Dominant Pedicle</b>	- Tensor fasciae latae flap	- Simple and reliable for small to medium defects.
	One major artery supplies the muscle.	- Gastrocnemius flap	- Used when a single reliable source is sufficient.
Type II	<b>Dominant Pedicle with Minor Pedicles</b>	- Gracilis flap	- Versatile with multiple blood sources.
	One dominant artery and one or more minor arteries.	- Soleus flap	- Good for areas requiring flexibility in blood supply.
Type III	<b>Two Dominant Pedicles</b>	- Gluteus maximus flap	- Provides reliable blood supply, even if one pedicle is compromised.
	Two major arteries from different sources.	- Rectus abdominis flap	- Useful for larger or more complex defects.
Type IV	<b>Segmental Pedicles</b>	- Sartorius flap	- Multiple segmental arteries supply different parts of the muscle.
	Several segmental arteries along the length of the muscle.	- Tibialis anterior flap	- Ideal for long and narrow defects.
Type V	<b>Dominant Pedicle with Secondary Segmental Pedicles</b>	- Latissimus dorsi flap	- Combines reliability of a dominant pedicle with added supply from segmental arteries.
	One major artery and several segmental arteries.	- Pectoralis major flap	- Suitable for large and extensive defects requiring robust blood supply.

#### Instructions

Flaps are utilized in a diverse range of scenarios in the field of reconstructive surgery. Common indications for this procedure include the repair of intricate skin abnormalities resulting from trauma, burns, or oncological resections. They are also employed for the treatment of innate abnormalities, such as cleft lip and palate, as well as for the restoration of breasts following mastectomy. Flaps are particularly beneficial in situations where there is insufficient local tissue or where vascularized covering is needed to enhance the survival of the transplanted tissue.

The appropriate choice of flap is contingent upon variables such as the dimensions and position of the imperfection, the condition of adjacent tissues, the accessibility of tissue from a donor, and the preferences of the patient. Conducting a comprehensive assessment of the patient is essential, including their overall health condition, any existing medical conditions, and variables that might impact the success of the flap, such as prior radiation treatment.

#### Complexities and Administration



**Figure 1. Flap principles in reconstructive surgery**

Although flaps are useful in correcting abnormalities, they can sometimes lead to problems. Flap necrosis, whether partial or entire, is a frequently seen complication that can be attributed to variables such as high stress, insufficient vascularization, or the presence of infection. Additional issues may arise, such as the development of bruising, seromas, wound infections, impaired healing, and changes in appearance.

Effective care of flap problems is crucial to maintain the viability and functionality of the transplanted tissue. This may entail conservative interventions, such as wound care, antibiotic administration, and enhancement of local blood supply. If there is partial tissue death, medical operations such as revision or flap revision may be done to eliminate the dead tissue and enhance the survival of the remaining flap. If the flap tissue dies completely, more serious measures may be required, such as employing other flaps or alternative procedures for secondary repair.

Close postoperative monitoring and ongoing follow-up of the patient are necessary for managing problems. Timely identification and treatment of complications are crucial to reduce their influence on ultimate outcomes and prevent further difficulties.

### Conversation

When considering flaps in reconstructive surgery, it is crucial to emphasize the benefits and difficulties that come with their use.

### Benefits

One significant benefit of flaps is the use of autologous tissue, which decreases the likelihood of immunological rejection and enhances the survival of the transplanted tissue. Furthermore, flaps aid to maintain the functionality and visual appeal of the impacted area, as the transplanted tissue preserves its inherent qualities, such as sensitivity and ability to contract. This is particularly pertinent in the context of

breast reconstruction, as autologous flaps offer a more authentic outcome and enhance the overall quality of life for patients.

Flaps possess a notable benefit in their capacity to effectively treat intricate faults. The diverse range of designs and the ability to integrate various tissues enable a customized reconstruction that is tailored to the specific requirements of each individual patient. The flaps also provide vascularized covering, which facilitates healing and minimizes the likelihood of problems, such as infection and necrosis.

### Obstacles

Although flaps in reconstructive surgery offer certain benefits, they also pose considerable difficulties. Choosing the appropriate flap is essential and necessitates a comprehensive assessment of the patient and meticulous preparation. Choosing the wrong flap might lead to difficulties, such as tissue death, because the recipient location does not receive enough blood supply.

Moreover, the execution of flaps necessitates specific surgical expertise and proficiency in microsurgery, particularly when dealing with free flaps. Performing microsurgical anastomosis of blood vessels is a crucial step in guaranteeing the life of a flap, and any mistake made during this stage might result in severe repercussions.

Another obstacle that may arise is the potential occurrence of postoperative complications, including infection and necrosis. These problems may undermine the ultimate outcome and necessitate more treatments for resolution.

### Final remarks

To summarize, flaps play a crucial role in reconstructive surgery by being an indispensable tool for repairing soft tissue deformities. Understanding the definition, signs, problems, and effective management of this is crucial for achieving good outcomes. Reconstructive surgeons can enhance patients' quality of life by utilizing their comprehensive

## An Analysis of Flaps in Reconstructive Surgery

knowledge of theoretical concepts, meticulous planning, and precise surgical technique to provide successful solutions. Flaps have notable benefits, including the use of one's own tissue, maintenance of functionality and appearance, and the capability to treat intricate deformities. Nevertheless, they also pose difficulties, such as the need for careful selection of flaps, the requirement for specific surgical expertise, and the task of effectively handling problems.

Research and technical advancements remain crucial in the domain of flaps in reconstructive surgery. Advanced imaging techniques, including as computed tomography and magnetic resonance imaging, have been developed to enhance the precision of tissue evaluation and improve preoperative planning. Furthermore, the progress made in microsurgery and vascular anastomosis techniques has enhanced the feasibility and results of free flaps.

Customization of the technique and utilization of several disciplines are also crucial factors in the effective deployment of flaps. Effective coordination among reconstructive surgeons, radiologists, anesthesiologists, and other healthcare providers is essential to guarantee meticulous patient evaluation, appropriate preoperative strategizing, and complete handling of difficulties.

With the progress in comprehending flap physiology and the enhancement of surgical procedures, the results of reconstructive surgery are anticipated to further improve. Promising avenues for future study include the identification of predictive biomarkers for flap viability, the use of adjuvant therapy to enhance vascularization, and the investigation of tissue engineering.

To summarize, flaps play a crucial role in reconstructive surgery by restoring the form, function, and appearance of damaged soft tissues. Despite the difficulties they pose, the appropriate utilization and efficient handling of complications can lead to favorable results for patients. Continued interdisciplinary research and collaboration are essential for further enhancing the effectiveness and results of flaps in reconstructive surgery.

## REFERENCES

- I. Gabrysz-Forget, F., Tabet, P., Rahal, A., Bissada, E., Christopoulos, A., & Ayad, T. (2019). Free versus pedicled flaps for reconstruction of head and neck cancer defects: a systematic review. *Journal of Otolaryngology-Head & Neck Surgery*, 48(1), 13.
- II. Götzl, R., Sterzinger, S., Arkudas, A., Boos, A. M., Semrau, S., Vassos, N., ... & Beier, J. P. (2020). The role of plastic reconstructive surgery in surgical therapy of soft tissue sarcomas. *Cancers*, 12(12), 3534.
- III. Wink, J. D., Gandhi, R. A., Ashley, B., & Levin, L. S. (2020). Flap reconstruction of the hand. *Plastic and Reconstructive Surgery*, 145(1), 172e-183e.
- IV. AlMugaren, F. M., Pak, C. J., Suh, H. P., & Hong, J. P. (2020). Best local flaps for lower extremity

reconstruction. *Plastic and Reconstructive Surgery-Global Open*, 8(4), e2774.

- V. De Almeida, Y. K., Krebs, M., Braun, M., Dap, F., Dautel, G., & Athlani, L. (2021). Innervation and vascular supply of the first dorsal interosseous muscle and palmar interosseous muscle of the index: An anatomic descriptive study. *Morphologie*, 105(351), 298-307.