

## Intestinal Tuberculosis with Enterocutaneous Fistula: A Rare Case

Delta Iswara<sup>1</sup>, Anggita Dian Karera<sup>2</sup>, Rachmad Aji Saksana<sup>3</sup>

<sup>1</sup>Faculty of Medicine, Jenderal Soedirman University, Purwokerto, JawaTengah

<sup>2</sup>An Ni'mah General Hospital, Wangon, Purwokerto, JawaTengah

<sup>3</sup>Margono Soekarjo General Hospital, Purwokerto, JawaTengah

### ABSTRACT

**Introduction:** Enterocutaneous fistula is a common postoperative complication. The incidence of enterocutaneous fistula as a complication of intestinal tuberculosis is quite rare, so we are interested in reporting this case.

**Case Report:** 32-year-old male presented with history of abdominal pain and fecal matter coming out from an opening in umbilical region for the past 1 month. Patient have history of laparotomy exploration 7 months ago and histopathology showed intestinal tuberculosis. Currently, patient was undergoing TB treatment with anti-tubercular treatment (ATT) for the seventh month. Physical examination showed fistulous opening 2x2 cm over the scar of previous laparotomy. Laboratory examination revealed leukocytosis shift to the left and hypoalbuminemia. Chest X-ray showed active pulmonary tuberculosis. Abdominal CT with with contrast showed localized ileus consist of sentinel loop and suggestive intestinal tuberculosis. Diagnosis of tubercular enterocutaneous fistula arising of as a post-operative complication was made. Patient was given intravenous fluids, antibiotics, antitubercular treatment, and wound care. Patient responded well to conservative management.

**Discussion:** Intestinal tuberculosis (TB) is the sixth most common site of extrapulmonary tuberculosis which can occur primary or secondary. Enterocutaneous fistula (ECF) is a rare complication of intestinal TB and can be managed based on whether the output is low or high. Conservative management can be done through administration of intravenous fluids, antibiotics, antitubercular treatment, and wound care

**KEYWORD:** extrapulmonary tuberculosis, intestinal tuberculosis, enterocutaneous fistula

### ARTICLE DETAILS

**Published On:**  
12 December 2023

**Available on:**  
<https://ijmscr.org/>

### INTRODUCTION

Tuberculosis (TB) can occur outside the lungs, which is called extra-pulmonary TB. Extrapulmonary TB accounted for 14% of the 6.4 million incident cases worldwide in 2017 and as much as 15% in Southeast Asia. Intestinal TB ranks 6<sup>th</sup> in the ranking of frequently occurring extrapulmonary TB and accounts for 2% of TB cases globally<sup>1,2</sup>.

The incidence of enterocutaneous fistula as a complication of intestinal tuberculosis is quite rare. Enterocutaneous fistula is an abnormal communication between the intestines and the skin. Nearly 80% percent of cases arise as post-operative complications. The remaining 20 to 30% are caused by trauma or spontaneously due to malignancy, radiation, inflammatory bowel disease, and intra-abdominal sepsis<sup>3</sup>. Fistula appearing 30 days after primary therapy such as surgery and radiotherapy are classified as spontaneous forms. Here we report a rare presentation of enterocutaneous fistula as a postoperative

complication and was proven to be from intestinal tuberculosis.

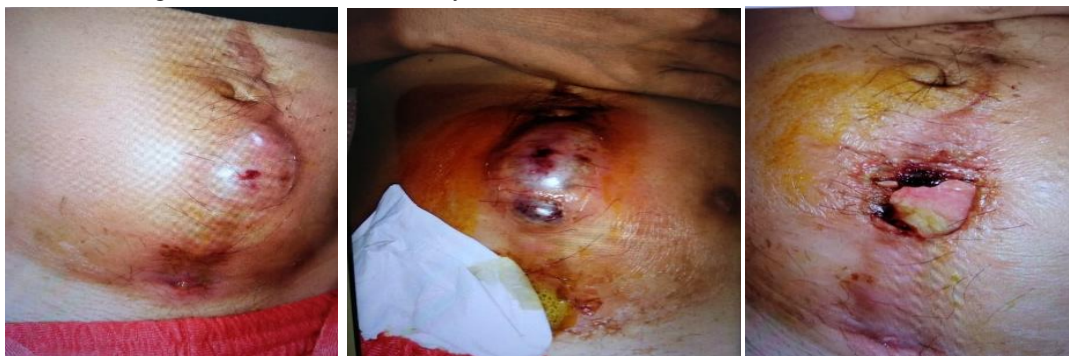### CASE REPORT

A 32-year-old male presented fecal matter coming out through an opening in umbilical region of his abdomen for the past 1 month. Initially, he had developed swelling in the skin of the umbilical region over the scar of previous laparotomy. The swelling had ruptured to discharge fecal matter with pus. Patient also complained fever before the swelling ruptured. There were no problems with defecation and micturition. Patient underwent laparotomy exploration 7 months ago and the biopsy showed intestinal tuberculosis (TB). Patient had been diagnosed with pulmonary TB and intestinal TB at the previous hospital. Currently, patient was undergoing TB treatment with anti-tubercular treatment (ATT) for the seventh month.

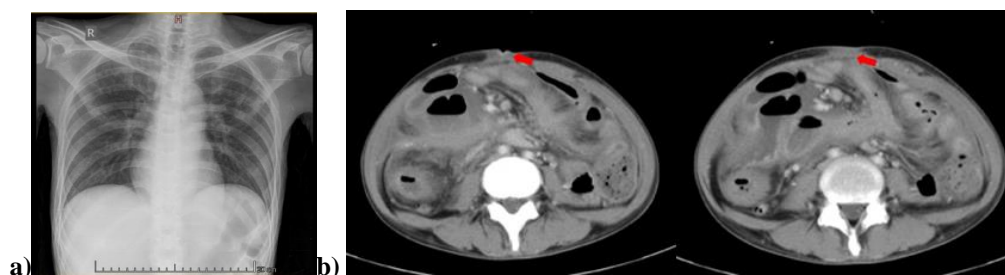
## Intestinal Tuberculosis with Enterocutaneous Fistula: A Rare Case

On physical examination, general condition appeared moderately ill with compos mentis consciousness. Vital sign was within normal limit. Patient was normoweight (height 165 cm; weight 50kg; and body mass index 18.35 kg/m<sup>2</sup>). On abdominal examination, there was 2x2 cm fistulous with fecal and pus soiling was seen over the scar of a previous surgery in umbilical region (**figure 1**). The 24-h fistula output on average 200mL. The routine laboratory investigations showed leucocytosis (16.180 u/L) with left shift and decreased serum albumin (2.63 g/dL). Liver function, kidney

function, blood sugar, and electrolytes were within normal limits. Chest X-ray examination showed active pulmonary tuberculosis (**figure 2a**). Patient underwent abdominal CT with contrast, the results showed localized ileus with sentinel loop; multiple mesenterial and para-aortic lymphadenopathy suggestive intestinal tuberculosis (**figure 2b**). Based on these results, patient was consulted to the digestive surgery department and decided for conservative management, fistula wound care, and re-hecting if the fistule is no longer active.



**Figure 1.** Fistulous opening over the scar of a previous laparotomy done 7 months back



**Figure 2. a.** Chest X-rays showed active pulmonary tuberculosis; **b.** Abdominal CT with contrast showed localized ileus with sentinel loop; multiple mesenterial and para-aortic lymphadenopathy suggestive intestinal tuberculosis

Diagnosis of tubercular enterocutaneous fistula arising from post-operative complication was made. The patient was managed conservatively for 2 weeks with intravenous fluids, antibiotics, continued antitubercular treatment, and local wound control. Patient received therapy intravenous albumin; inj ceftriaxone 1gr/12hr; inj metronidazole 500mg/8hr; analgesics drug; antitubercular treatment (ATT) 2FDC, 3 tablets/day; albumin supplement; and high protein-calorie, low-fiber diet. The fistula site was covered with a stoma bag to collect the affluent and protect the surrounding skin. Regular monitoring of the hematological parameters and fistula output was done. After 2 weeks, there was a significant improvement in the symptoms, fistula output gradually reduced to nil and the wound dried up, hematological parameters and serum albumin became normal. Patient was discharged from the hospital and planned for routine control at internal medicine clinic.

### DISCUSSION

Tuberculosis is common disease in developing countries and manifests in different ways. Intestinal tuberculosis is the sixth most common site of extra-pulmonary tuberculosis. Intestinal

tuberculosis (TB) may be a primary or secondary infection, usually following a primary pulmonary focus<sup>4,5</sup>. In this case, the intestinal TB that occurred was probably secondary TB where the patient, apart from complaining of abdominal pain, also complained of coughing and a chest X-ray showed active pulmonary TB.

Patient with intestinal tuberculosis commonly present with colic abdominal pain, abdominal distention, nausea and vomiting, constipation, and diarrhoea. Ileocecal region is the most common site of intestinal tuberculosis, and probably related to increased lymphoid tissue and stasis<sup>5,6</sup>. The infection sources include swallowed infected sputum, hematogenous or contiguous spread from adjacent organs or contaminated food. Complications of intestinal tuberculosis include intestinal obstruction (31.7%), intestinal perforation (4.9%) and small bowel volvulus (2.4%). Rarely, intestinal tuberculosis may present with enterocutaneous fistula (ECF) or spontaneous ECF (2.4%)<sup>6</sup>.

Enterocutaneous fistula is an abnormal connecting between digestive tract and the skin. The great majority of enterocutaneous fistula are iatrogenic (75-85%) and rest (15-25%) occur spontaneously as part of the disease process in

## Intestinal Tuberculosis with Enterocutaneous Fistula: A Rare Case

Crohn's disease, diverticulitis, tuberculosis, or enteric fever<sup>4,7,8</sup>. Enterocutaneous fistula is associated with significant morbidity and mortality (estimated between 10 and 20%). Enterocutaneous fistula often leads to nutritional deficits, septic complications and concomitant diseases that may appear as a result of prolonged hospital stay or death complication<sup>8,9</sup>. Several pathomechanisms that explain enterocutaneous tuberculosis: 1) Extension of bowel disease to surrounding structures, 2) Extension of adjacent non-bowel disease to normal bowel. 3) Inadvertent or unrecognized injury to the bowel and 4) Anastomosis disruption<sup>7</sup>.

Though not spontaneous in its strict sense, a spontaneous enterocutaneous fistula is defined as a fistula that occurs 30 days after primary therapy has been performed such as surgery or radiotherapy<sup>9</sup>. Our case was discovered after 7 months of laparotomy, and pre-existing intestinal tuberculosis appeared to be a risk factor for the formation of enterocutaneous fistula after surgery. The same case was reported by Pahwa & Girotra where tubercular enterocutaneous fistulae were reported in two cases during the post-operative period<sup>10</sup>

Initial management of enterocutaneous fistula consist of its identification followed by correction of fluid and electrolyte imbalance, aggressive treatment of sepsis, control of fistula output, attention to wound care, and psychological support<sup>8,11</sup>. Enterocutaneous fistulas can be managed based on whether the output is low (<200–500 ml/24 hours) or the output is high (>500 ml/24 hours). High-output fistulas usually require surgical management and involve removal of the fistula tract with resection and anastomosis of the involved part of the bowel. Low-output fistula can be managed conservatively in patient with stable condition with no evidence of sepsis or localized infection. Under certain conditions, conservative treatment does not guarantee definitive resolution of the fistula. However, surgical treatment must be planned carefully and used when conservative treatment fails<sup>8,12</sup>.

In our case, patient had low-output fistula and was managed conservatively. The patient responded well to therapy within 2 weeks. The success of conservative management was also demonstrated in a case report by Shah & Wani where the patient experienced a spontaneous tubercular enterocutaneous fistula in the right gluteal region and experienced improvement in symptoms after being treated with antibiotics, intravenous fluids, and antisecretory agents<sup>12</sup>. Research by Taggarshe et al., which compared conservative vs surgical treatment of enterocutaneous fistula in a community teaching hospital over decade showed that 34 of 45 patients with low-output fistulae were more successfully treated with conservative management<sup>13</sup>. Singh et al. reported enterocutaneous fistula over scar of a previous appendectomy and response was uneventful after fistulotomy and ATT for nine months<sup>14</sup>.

Patient with an increased probability of spontaneous fistula closure with conservative management include patient

with surgical, appendicitis, and diverticulitis etiology; transferrin >200mg/dL; no obstruction, bowel in continuity, no infection, no inflamed intestine; length >2cm, distal anatomic location, single opening; low daily output <200mL/24h; no sepsis, balanced electrolytes; and initial referral to tertiary care center<sup>15</sup>. The most common risk factors associated with non-healing fistulas are foreign body radiation, inflammation, infection, inflammatory bowel disease, epithelization of the fistula tract, neoplasm and distal obstruction<sup>8</sup>.

## CONCLUSION

Enterocutaneous fistula is a possible complication of abdominal surgery and pre-existing intestinal tuberculosis. Successful management requires multidisciplinary approach. Conservative management should always be the first choice, as long as the fistula output is low and the patient's condition allows non-surgical management.

## REFERENCES

- I. Djaharuddin I, Hatta M, Tabri NA, Muis E, Safriadi S, Primaguna MR. Intestinal tuberculosis: Case series of three patients. *Respir Med Case Rep* 2020;29:1–4.
- II. Putranto AS, Muchtar S. Anastomosis in Intestinal Tuberculosis: A Systematic Review. *The New Ropanasuri Journal of Surgery* 2018;3(2):38–43.
- III. Cowan K, Cassaro S. *Enterocutaneous Fistula*. Treasure Island (FL): StatPearls Publishing, 2023.
- IV. Bakhshi GD, Jadhav K V, Choure DD, Tayade MB, Jaiswal P, Anand A. Spontaneous Tuberculous Enterocutaneous Fistula at Iliac Crest – A Rare Case. *Journal of Medical Science And clinical Research* 2015;3(9):7649–7652.
- V. Balachandra D, Nag HH, Sakhuja P, Barman S. Tuberculosis of intestine with concurrent complex enterovesical and enterocutaneous fistula. *Journal of Clinical and Diagnostic Research* 2018;12(7):3–5.
- VI. Tan J, Porter D, Guo J, Pan L, Yang G, Zhang Z. A Neglected Case of Colonic Tuberculosis With Thoracolumbar Enterocutaneous Fecal Fistulae. *J Med Cases* 2020;11(5):111–114.
- VII. Wanjara S, Makanga W. Spontaneous Bilateral Lumbar Region Colocutaneous Fistulae. A Case Report. *Annals of African Surgery* 2023;20(2):45–50.
- VIII. Musa N, Aquilino F, Panzera P, Martines G. Successful conservative treatment of enterocutaneous fistula with cyanoacrylate surgical sealant: case report. *G Chir* 2017;38(5):256–259.
- IX. Arimino S, Arijainalalao N, Rakotomena D, Rajaonarivony T, Rakoto H. Enterocutaneous Fistula Developing In The Scar of an Appendectomy With an Abdominal Tuberculosis: A Case Report. *Journal of Medicine and HealthCare [homepage on the Internet]* 2019;1(1):1–2.

## **Intestinal Tuberculosis with Enterocutaneous Fistula: A Rare Case**

- X. Pahwa M, Girotra M. Role of Early Surgery in Spontaneous Enterocutaneous Tubercular Fistulae. *Studi J Gastroenterol* 2010;16(4):305.
- XI. Ghimire P. Management of Enterocutaneous Fistula: A Review. *Journal of the Nepal Medical Association* 2022;60(245):93–100.
- XII. Shah M, Wani M. Spontaneous tubercular enterocutaneous fistula. *Saudi J Med Med Sci* 2017;5(3):275.
- XIII. Taggarshe D. Management of enterocutaneous fistulae: A 10 years experience. *World J Gastrointest Surg* 2010;2(7):242.
- XIV. Singh O, Gupta S, Moses S, Jain DK. The Saudi Journal of Gastroenterology Spontaneous Tubercular Enterocutaneous Fistula Developing in the Scar of a Surgery Done 14 Years Earlier. *The Saudi Journal of Gastroenterology* 2009;15(4):261–264.
- XV. Gribovskaja-Rupp I, Melton GB. Enterocutaneous Fistula: Proven Strategies and Updates. *Clin Colon Rectal Surg* 2016;29(2):130–137.