

The Manifestations of Skin Lesion on COVID-19 Patients: A Systematic Review

Monica Trifitriana¹ MD¹, Rido Mulawarman², Yuli Kurniawati, MD³

¹Doctor Education Program, Faculty of Medicine, Sriwijaya University, Palembang, Indonesia

²Doctor Education Program, Faculty of Medicine, Sriwijaya University, Palembang, Indonesia

³Department of Dermatology, Venereology, and Aesthetics, Sriwijaya University, Palembang, Indonesia

ABSTRACT

Introduction: The 2019 Coronavirus Disease (COVID-19) is a respiratory tract infection caused by severe acute respiratory syndrome coronavirus 2 (SARS-CoV-2) that spread rapidly worldwide through human-to-human transmission. Skin is one of the target organs that involvement in adults and children affected by the novel coronavirus SARS-CoV-2. Despite the pathophysiologic mechanisms of cutaneous manifestations still unclear.

Objective: We aim to assess the latest evidence of skin lesions associated with Covid-19 patients with a detailed analysis of skin morphology for early diagnosis and lead to possible better prognosis in COVID-19 patients.

Method: We performed a comprehensive search on topics that assessed the manifestations of skin lesions in Covid-19 Patients from inception until February 2022.

Result: There were 25 studies out of a total of 2450 patients divided into six patterns of skin lesions that occur in the presence of COVID-19 infection, including maculopapular, urticarial, pseudo-chilblain, vesicular, petechiae/purpura and livedoid. Among these skin lesions, maculopapular and pseudo-chilblains lesions appear to be the most common, followed by urticarial, vesicular, livedoid, and petechial/purpura. These lesions have been found in people of all age groups, including children.

Conclusion: In conclusion, this systematic review supplied a complex and detailed analysis of 6 central dermatology patterns common in COVID-19 patients explaining the underlying molecular mechanisms. Another future study on cutaneous manifestations related to COVID-19 is still needed for detailed analysis.

KEYWORDS: Cutaneous manifestation, skin lesions, COVID-19, Systematic Review

ARTICLE DETAILS

Published On:
16 November 2023

Available on:
<https://ijmscr.org/>

I. INTRODUCTION

The 2019 Coronavirus Disease (COVID-19) is a respiratory tract infection caused by severe acute respiratory syndrome coronavirus 2 (SARS-CoV-2).^{1,2} SARS-CoV-2 spread rapidly worldwide through human-to-human transmission until World Health Organization (WHO) announced coronavirus 2019 disease (COVID-19) as a pandemic condition on March 11.³ The asymptomatic transmission, high infection rate, and high mortality rate among the elderly and immunocompromised associated with this disease.² On August 2020, 20 million cases of COVID-19 have been confirmed globally, with more than 750,000 deaths reported in over 200 countries and territories.^{1,2} The main clinical manifestations of COVID-19 were fever, dry cough, sore

throat, and fatigue. While sputum production, dyspnoea, and muscle aches were less commonly reported.⁴

SARS-CoV-2 is a novel enveloped, positive-sense, single-stranded RNA virus related to the genus Betacoronavirus.¹ Angiotensin-converting enzyme 2 (ACE2) is a protein that functions as the receptor to SARS-CoV-2 to invade cells and cause infection in humans.^{1,2} Covid-19 binds to Angiotensin-converting enzyme 2 (ACE2) receptors that are located not only in the lung alveolar epithelial cells, nasopharyngeal, and oral mucosa but also in the endothelium and vascular smooth muscle cells, brain, gut, and peripheral organs consist of liver and kidney. This theory represents that the manifestation clinic of Covid-19 is not limited to local pneumonia but could be a multisystem illness involving different organs.⁵

The Manifestations of Skin Lesion on COVID-19 Patients: A Systematic Review

Skin is one of the target organs that involvement in adults and children affected by the novel coronavirus SARS-CoV-2 and in response to the current COVID-19 pandemic. Six The pathway of SARS-CoV-2 invading the skin is strongly associated with the Angiotensin-converting enzyme 2 (ACE2) receptor.^{5,6} The expression of ACE2 was significantly higher in keratinocytes than in other cellular compartments in skin tissues, such as fibroblasts and melanocytes. Out of all ACE2-positive cells in the skin, keratinocytes account for 97.37%, followed by sweat gland cells 2.63%. The widespread expression of ACE2 suggests that this virus might be responsible for infecting other human tissues alongside the lungs and could potentially result in additional clinical manifestations.⁷

The cutaneous manifestations related to COVID-19 have widely been reported in some studies.^{7,8} Early data from China reported skin symptoms were present in only 0.2% of 1099 confirmed COVID-19 cases. However, data from Italy later revealed a higher percentage of skin manifestations in 20.4% of 88 positive COVID-19 patients.⁸ Although differences in prevalence, skin lesion-related COVID-19 have become increasingly common in many age groups, including children who were to be asymptomatic infection. Despite the unclear pathophysiologic mechanisms of cutaneous manifestations, their identification may be vital to early diagnosis and lead to a better prognosis in COVID-19 patients. The typical pattern of skin lesions of COVID-19 disease had the main six dermatological patterns associated with COVID-19 such as maculopapular/morbilliform, urticarial, vesicular, chilblain-like, petechiae/purpura, and

livedoid.^{5,6} an algorithm has been published to provide for easier classification of the main COVID-19 skin findings due to scientific need for appropriate classification of these cutaneous manifestations.

This systematic review supplies a detailed analysis of skin morphology related to COVID-19 to early diagnosis and leads to a possible better prognosis in COVID-19 patients, particularly in children with asymptomatic infection.

II. METHODS

Search strategy

We performed a comprehensive search on the topic that assesses Manifestations of skin lesions related to Covid-19 Patients with keywords "COVID-19," "coronavirus," or "SARS-CoV-2" in combination with relevant terminology such as "skin," "cutaneous," "chilblain-like," "maculopapular," "urticarial," "livedo," "vesicular," and "petechiae," and its synonym from inception up until February 2022 from electronic databases including Pubmed, Europe PMC, Cochrane Central Database, ClinicalTrials.gov, and Mendeley. The records were then systematically evaluated using inclusion and exclusion criteria. Two authors (MT and RM) independently performed an initial search (scanned all abstracts to find relevant studies). When discrepancies occurred, a third author (YK) made the final judgment and assessed eligibility from full-text articles, with a similar process for potential disagreements as described above. A preferred reporting item for the Systematic Reviews flowchart of the literature search strategy of studies was presented in Figure 1.

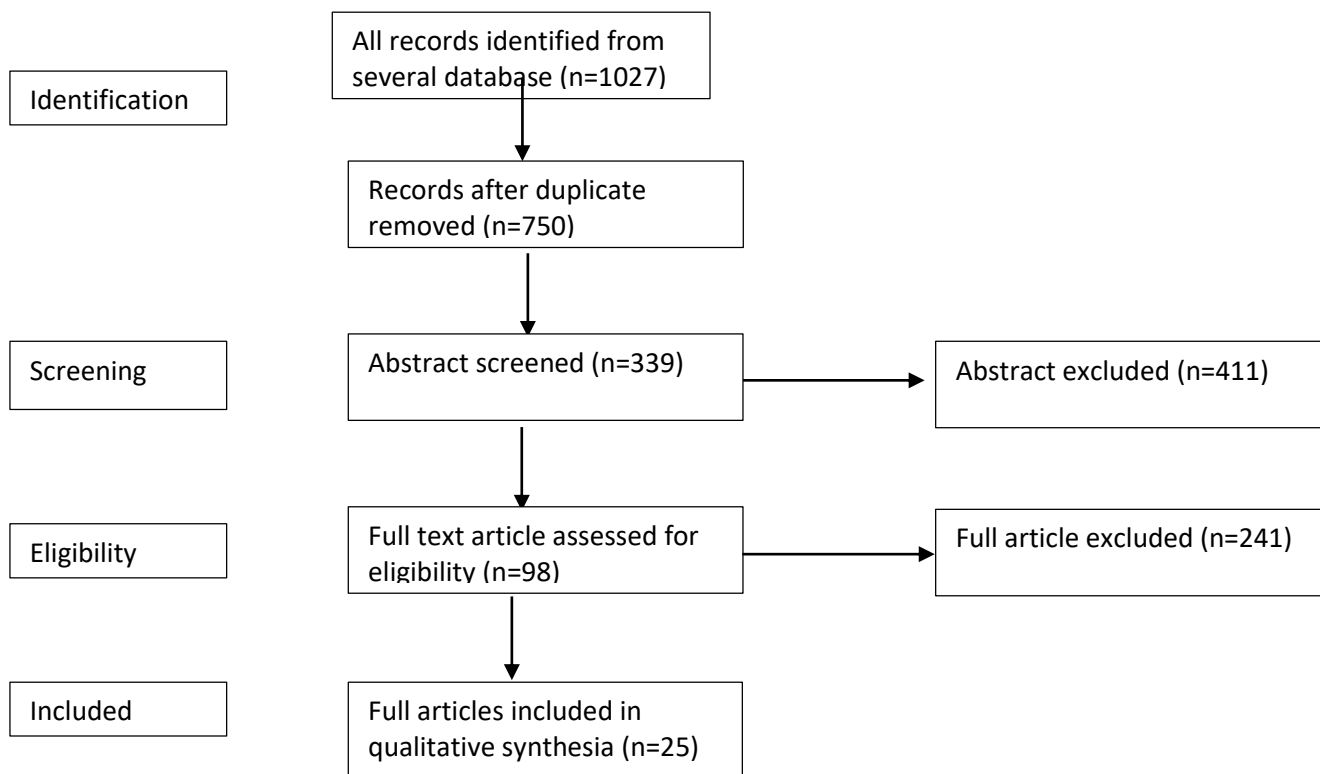


Figure 1. The PRISMA flow diagram

The Manifestations of Skin Lesion on COVID-19 Patients: A Systematic Review

Selection Criteria

The inclusion criteria for this study are all studies that assess Manifestations of skin lesion association with Covid-19 Patients. Study design from the selected publications included case reports, case series, prospective and retrospective cohort studies, case-control studies, and clinical trials. The exclusion criteria for this study are studies that did not report cutaneous manifestations and study design, such as Review articles, meta-analyses, and editorials.

Data Extraction

Data extraction and quality assessment were done by three independent authors (MT, RM, YK) using standardized extraction, which includes authors, year of publication, total patients, mean age, gender, population of covid-19 patients with cutaneous manifestations, and the distribution of cutaneous manifestations. Each made the table data for data extraction of six central dermatological patterns of COVID-19 are described as maculopapular/morbilliform, urticarial, vesicular, chilblain-like, petechiae/purpura, and livedoid

III. RESULT

The manifestations of skin lesions associated with COVID-19 infection are numerous and varied when compared. The six central dermatological patterns of COVID-19 were described as maculopapular/morbilliform, urticaria, vesicular, chilblain-like/pseudo-chilblain, petechiae/purpura, and lived. These clinical findings were classified as inflammatory (maculopapular/morbilliform, urticaria, vesicular) or vascular lesions (e.g. chilblain, petechiae/purpura, and lived).⁶ an algorithm has been published to facilitate the classification of the previously mentioned major skin findings of COVID-19 for the precise scientific need of these skin manifestations.

1. Maculo-popular rash

Maculo-popular lesions are the most common skin manifestation experienced by COVID-19 patients. These lesions are often the result of an adverse drug reaction or viral infection.⁹ Children who develop maculopapular lesions are usually the result of a viral infection, whereas drug eruptions are usually the trigger for these lesions in adults.¹⁰

Maculopapular lesions are commonly encountered in COVID-19 patients presenting with cutaneous manifestations (Table 1). From the results (table 1), 375 patients with skin lesions associated with COVID-19 identified a 45% prevalence of maculopapular lesions.⁹⁻²⁰ The prevalence of these lesions varies across studies, with smaller cases ranging from 5% to 70%. Many of the maculopapular rashes reported were observed in middle-aged or elderly patients.^{10,11,16,17,18,19,20} However, some cases have appeared in younger adults.^{13,14} According to the location of cutaneous lesions, most of these lesions are located on the trunk.^{9,10,11,12,15,17,18,19,20} Another common location beside the trunk is the limbs.^{9,10,12,14,17,19} from the Dalal et al. study stated that macular popular lesions in some patients infected with COVID-19 had Presented centripetal distribution.¹² Mostly population of males has macular-papular lesion greatly than females. The mean duration of the exanthems ranged from 8.6 days to 11.6 days.¹¹ According to some studies, pruritus was present in 50% of patients with maculopapular lesions.¹³ Importantly, the same study showed that maculopapular rash was associated with greater severity of COVID-19 infection; this is supported by the 2% mortality rate reported in patients with this lesion.¹¹

Several theories discuss the molecular mechanism of maculopapular lesions.¹⁶ From Galvan et al. study mentioned that these lesions are not very helpful in diagnosis because of the potential cause of adverse drug reactions.¹⁶ This is true because patients with maculopapular lesions have more severe infections and therefore receive greater drug therapy.¹⁴ Potential drugs given to cure COVID-19, such as Ribavirin, Colchicine, IVIG treatment, Lopinavir, Ritonavir, and other antiretroviral drugs, are known to cause skin side effects similar to maculopapular and morbilliform rash.¹⁶ However, maculopapular lesions have been observed in a new treatment-free case series, suggesting that these lesions may not be drug-associated.¹³ Herrero-Moyano et al. hypothesised that a cytokine storm generated by a hyperactive immune system could trigger these lesions after observing a late-onset maculopapular eruption.¹⁷

Table 1. Baseline Characteristic and further explanation of maculopapular lesions in COVID-19 patients

Author, Year	Total Patients COVID-19	Mean Age (years)	Gender	Cutaneous Manifestations	Location cutaneous manifestations
Almeida et al, 2021 ⁹	Skin lesion (+): 45 Skin lesion (-): 0	37.2 ±19.68	M: 26 F: 19	Macular popular(+): 22	Trunk (n=18) Limbs (n=4) Scalp (n=3)
Askin et al, 2020 ¹⁰	Skin lesion (+): 34 Skin lesion (-): 88	M: 57.44 ±17.259 F: 58.80 ± 15.918	M: 90 F: 32	Macular popular(+): 12	Trunk (n=12) One case → on the limbs

The Manifestations of Skin Lesion on COVID-19 Patients: A Systematic Review

Cerdeira et al, 2021 ¹¹	Skin lesion (+): 32 Skin lesion (-): 0	45.55 ±20.18	M: 19 F: 13	Macular popular(+): 5	Trunk (n=5) Generalized (n=1)
Dalal et al, 2020 ¹²	Skin lesion (+): 13 Skin lesion (-): 89	39.3 ±17.9	M: 95 F: 7	Macular popular(+): 3	Trunk (n=3) Limbs (n=1) Presented centripetal distribution
De masson et al, 2020 ¹³	Skin lesion (+): 277 Skin lesion (-): 0	27	M: 129 F: 148	Macular popular(+): 25	Trunk (n=25) Face (n=2)
Docampo simon et al, 2020 ¹⁴	Skin lesion (+): 58 Skin lesion (-): 0	14	M: 29 F: 29	Macular popular(+): 3	Feet (n=36) Hand (n=9) Hands and Feet (n=13)
Fattori et al, 2021 ¹⁵	Skin lesion (+): 6 Skin lesion (-): 0	N/A	N/A	Macular popular(+): 6	Trunk (n=6) Limbs (n=2)
Galvan, 2020 ¹⁶	Skin lesion (+): 375 Skin lesion (-): 0	55.3 ±20.2	M: 153 F: 222	Macular popular(+): 176	Perifollicular distribution → dorsum of hand
Herrer-Moyano et al, 2020 ¹⁷	Skin lesion (+): 8 Skin lesion (-): 1169	72.2 ±57.88	Mostly male	Macular popular(+): 8	Trunk (n=7) Limbs(n=2) Face (n=2)
Marzano et al, 2021 ¹⁸	Skin lesion (+): 200 Skin lesion (-): 0	40.25± 72.25	M: 108 F: 92	Macular popular(+): 48	Trunk (n=48) Limbs(n=10) Face (n=1)
Reymundo et al, 2020 ¹⁹	Skin lesion (+): 7 Skin lesion (-): 11	66.57 ±57.82	M: 6 F: 12	Macular popular(+): 7	Trunk (n=7) Proximal upper limbs (n=6) Lower limbs (n=1)
Rubio-Muniz et al, 2020 ²⁰	Skin lesion (+): 34 Skin lesion (-): 0	54.5± 31.66	M: 14 F: 20	Macular popular(+): 10	Trunk (n=10)

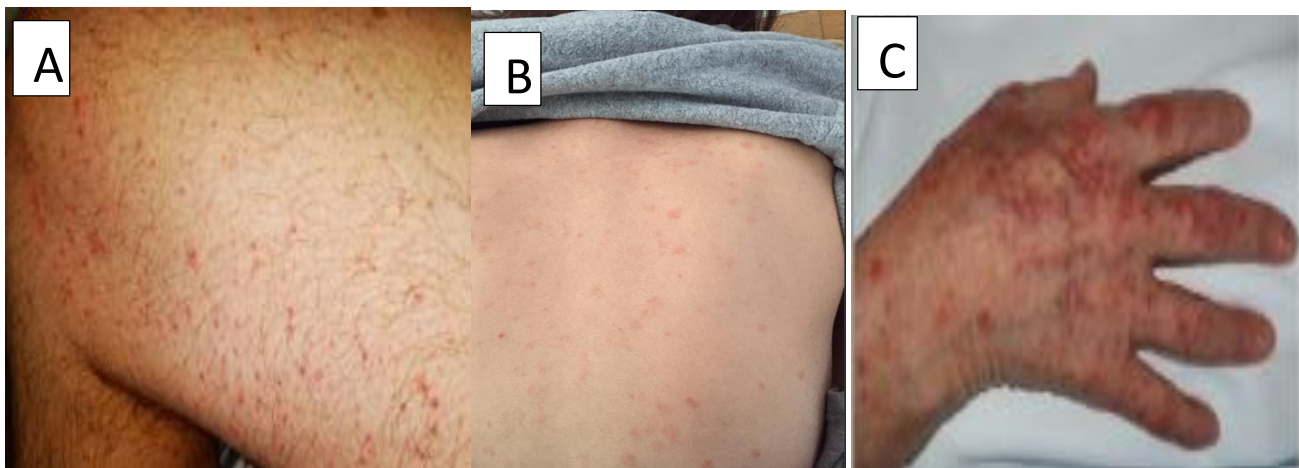


Figure 2. Image of maculopapular rash in COVID-19 patients. (A) Maculopapular lesion with perifollicular distribution on the lower limb, (B) Maculo-papular lesion appearing on the trunk, (C) maculopapular on dorsum of the hand.^{11,15,17}

2. Urticaria

Urticarial lesions have also been found in several case series of COVID-19 cases, although not as much as in maculopapular lesions. These lesions typically present as hives or angioedema and can be characterized as an erythematous slightly raised papular rash followed by intense pruritic sensations.²¹ During the COVID-19 pandemic, urticarial lesions were considered one of the most common skin manifestations, even though urticarial lesions had been relatively common in dermatological conditions before the pandemic. Acute urticaria, a self-limiting lesion lasting less than six weeks, has been reported in 20% of the general population.²¹⁻²², whereas chronic urticaria, a recurrent lesion occurring for more than six weeks, appears to affect 5% of the general population.²² Confounding factors for these lesions are viral/bacterial/parasitic infections, environmental exposures, and IgE-mediated allergic reactions in response to drugs, food, or biting insects.²³ Urticaria lesions are usually self-limiting lesions after removal of the causative agent, but in some severe cases, antihistamines and steroids have been applied for symptomatic relief.

From Table 2, acute urticarial lesions often occur in several COVID-19 studies.^{9,10,21,11,12,22,13,16,23,18,24,20,25} Prevalence of these lesions, among other skin manifestations, has varied from 7% up to 40% in smaller case series. These

lesions were common among middle-aged up to older patients.¹³ Most of these lesions were located on the trunk or limbs.^{9,11,22} In several cases, this lesion was generalized to the full body or localized to the face.^{9,10,11,25} Males' prevalence is higher than females.^{9,11,22,25} The onset of urticarial lesions relates to COVID-19 with an average duration of 6.8 days.²¹ Galván Casas et al. reported pruritus in 92% of patients with urticarial lesions and associated these lesions with a more severe COVID-19 infection.¹⁶

Because many urticaria cases are therapy-related, a possible cause of urticarial lesions may involve drug-induced exanthema.¹⁶ Urticaria is often described as a skin side effect in many potent anti-COVID-19 drugs such as chloroquine, hydroxychloroquine, lopinavir/ritonavir, nitazoxanide, corticosteroids, baricitinab, IVIG treatments, and checkpoint inhibitors.²¹ In addition to the adverse drug effects, another possible pathophysiological mechanism leading to urticaria is the overactivity of the immune system resulting in a potential “cytokine storm” involving the skin.²³⁻²⁴ Finally, the direct skin effect of the SARS-CoV-2 virus is the main cause, given that viral infection has sometimes been implicated as the main agent in cases of urticaria. Due to the extreme variability in the aetiology of urticarial skin lesions, these lesions are considered a potentially inaccurate marker for the diagnosis or verification of COVID19.²³

Table 2. Baseline Characteristic and further explanation of urticarial lesions in COVID-19 patients

Author, Year	Total Patients COVID-19	Mean Age (years)	Gender	Cutaneous Manifestations	Location cutaneous manifestations
Almeida et al, 2021 ⁹	Skin lesion (+): 45 Skin lesion (-): 0	37.2 ±19.68	M: 26 F: 19	Urticarial(+): 9	Trunk (n=9) Limbs (n=5) Generalized (n=1)
Askin et al, 2020 ¹⁰	Skin lesion (+): 34 Skin lesion (-):	M: 57.44 ±17.259 F:	M: 90 F: 32	Urticarial(+): 7	Generalized

The Manifestations of Skin Lesion on COVID-19 Patients: A Systematic Review

		88	58.80 ± 15.918			
Bouaziz et al, 2020 ²¹	Skin lesion (+): 14 Skin lesion (-): 0	N/A	N/A		Urticarial(+): 1	N/A
Cordeira et al, 2021 ¹¹	Skin lesion (+): 32 Skin lesion (-): 0	45.55 ±20.18	M: 19 F: 13		Urticarial(+): 6	Trunk (n=7) Upper and lower limbs (n=4) Face (n=2)
Dalal et al, 2020 ¹²	Skin lesion (+): 13 Skin lesion (-): 89	39.3 ±17.9	M: 95 F: 7		Urticarial(+): 2	Trunk (n=2)
De giorgi et al, 2020 ²²	Skin lesion (+): 53 Skin lesion (-): 625	55.9 ±28.69	M: 32 F: 21		Urticarial(+): 14	Trunk (n=14) Upper limbs (n=2)
De masson et al, 2020 ¹³	Skin lesion (+): 277 Skin lesion (-): 0	27	M: 129 F: 148		Urticarial(+): 26	Trunk and limbs (n=24) Face (n=2)
Galvan, 2020 ¹⁶	Skin lesion (+): 375 Skin lesion (-): 0	55.3 ±20.2	M: 153 F: 222		Urticarial(+): 73	Mostly on trunk A few cases on palms
Gaspari et al, 2020 ²³	Skin lesion (+): 18 Skin lesion (-): 2	51	M: 17 F: 3		Urticarial(+): 2	Left hand (n=2)
Marzano et al, 2021 ¹⁸	Skin lesion (+): 200 Skin lesion (-): 0	40.25± 72.25	M: 108 F: 92		Urticarial(+): 19	Trunk (n=19)
Recalcati et al, 2020 ²⁴	Skin lesion (+): 18 Skin lesion (-): 70	N/A	N/A		Urticarial(+): 3	Trunk (n=3)
Rubio-Muniz et al, 2020 ²⁰	Skin lesion (+): 34 Skin lesion (-): 0	54.5± 31.66	M: 14 F: 20		Urticarial(+): 3	Trunk (n=3)
Yildiray et al, 2021 ²⁵	Skin lesion (+): 5 Skin lesion (-): 0	54.5± 31.66	M: 2 F: 3		Urticarial(+): 3	Trunk and limbs (n=4) Face (n=1)

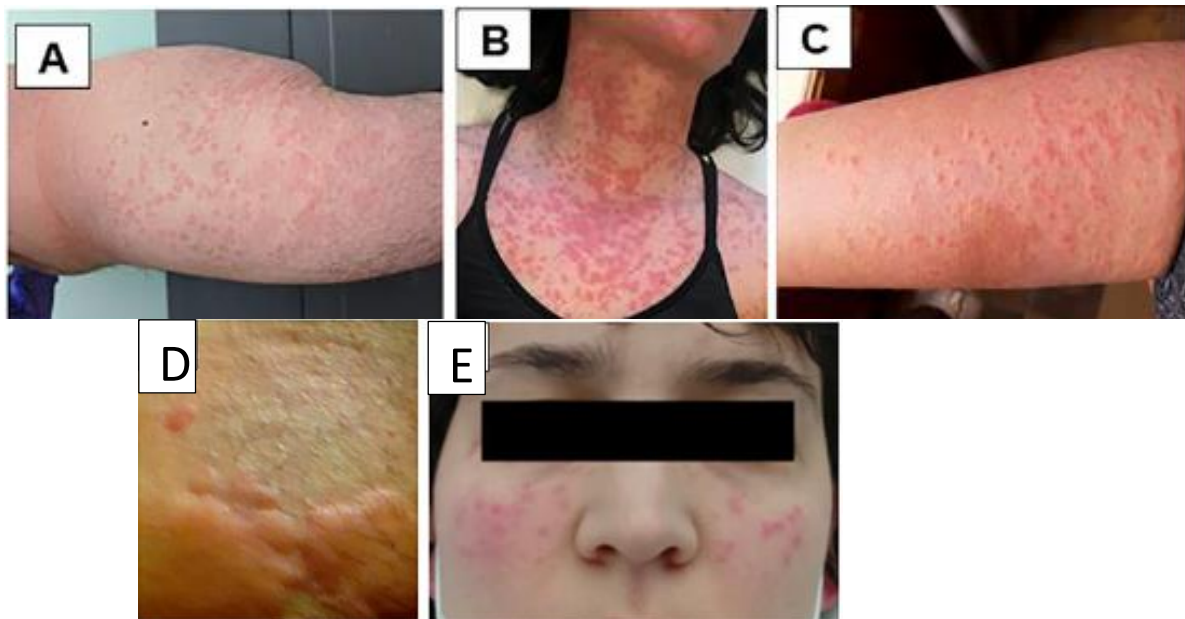


Figure 3. Image of Urticarial lesions in COVID-19 patients. (A) urticarial lesions on proximal lower limbs. (B) Urticarial lesion is the same as hives on the neck and chest. (C) Generalized urticarial lesion. (D) urticarial lesion on the trunk. (E) Urticarial lesion on face²¹⁻²⁵

3. Pseudo-chilblain

Chilblain lesion, called pernio, is a localized inflammatory skin disorder caused by exposure to cold temperatures or a moist environment resulting in swelling and discoloration of the extremities.²⁶ The increased incidence of pernio/acral-like or chilblain-like lesions, coupled with the temporal association with viral symptoms, are often called “COVID toes.”²⁷ The term is derived from a skin condition in the toes that appears as an erythematous or purplish lesion. In some cases, it is idiopathic; other literature suggests that chilblain is associated with autoimmune diseases such as lupus.²⁶⁻²⁷ In some cases, the pathogenesis behind chilblains is not fully understood. One of the most frequently discussed mechanisms of cold-induced vasoconstriction and vasospasm causes hypoxemia and inflammation. Some theories also suggest hyper-viscosity or autoantibody-induced endothelial damage. Treatment modalities include warming, NSAIDs, topical steroids, and vasodilators.²⁷

A skin lesion similar to the chilblain condition described above referred to as chilblain-like or pernio-like, is also currently the most common skin manifestation of COVID-19, partly because of the many published studies on it (Table 3). From the result (table 3), 2087 patients with skin lesions associated with COVID-19 identified a 65% prevalence of pseudo-chilblain lesions.^{9,26,21,11,27,13,14,28,29,30,31,16,32} The prevalence of these lesions varied considerably between studies. These skin

lesions were commonly identified among adolescents and young adults.^{26,27,14,29,30,31,32,24} Locations of pseudo-chilblain lesions were consistently being affected on feet and hands.^{26,27,14,29,30,31,32,24} On the hands and feet, the acral lesions typically localize on the fingers and toes, respectively. The duration onset of pseudo chilblain lesions was almost always after the onset of COVID-19’s systemic symptoms, and they normally lasted for about a week or two on average.²⁶ In another case, chilblain-like/pseudochilblain lesions were identified in 55% of cases.³² On Galvan et al. stated that the symptoms of pseudochilblain lesion commonly with pain and pruritus.¹⁶ Many of the patients presenting with pernio-like lesions were young and healthy. These rashes were typically associated with relatively mild COVID-19 infections.¹⁶

Another research hypothesized the pathophysiology behind chilblain association with “immune dysregulation, vasculitis, vessel thrombosis or neoangiogenesis.”²¹ It related to previous cases with acro-ischemia and DIC (disseminated intravascular coagulation) from initial reports from Wuhan, China. The three main hypotheses of the paper were confounding factors, post-viral immune response, or immune anti-viral response.²¹ The most recent studies have not stated that pseudo-chilblain skin lesions associate with positive COVID-19 infection. Therefore these lesions should not be considered an accurate indicator for the diagnosis of COVID-19.³²

The Manifestations of Skin Lesion on COVID-19 Patients: A Systematic Review

Table 3. Baseline Characteristic and further explanation of pseudo-chilblain lesions in COVID-19 patients

Author, Year	Total Patients COVID-19	Mean Age (years)	Gender	Cutaneous Manifestations	Location cutaneous manifestations
Almeida et al, 2021 ⁹	Skin lesion (+): 45 Skin lesion (-): 0	37.2 ±19.68	M: 26 F: 19	pseudo-chilblain (+): 16	Trunk & Toes (n=16) Limbs (n=5) Face (n=2)
Andina et al, 2020 ²⁶	Skin lesion (+): 22 Skin lesion (-): 0	12 ± 6.17	M: 13 F: 9	pseudo-chilblain (+): 22	Toes (n=22) Fingers (n=3)
Bouaziz et al, 2020 ²¹	Skin lesion (+): 14 Skin lesion (-): 0	N/A	N/A	pseudo-chilblain (+): 2	N/A
Cerdeira et al, 2021 ¹¹	Skin lesion (+): 32 Skin lesion (-): 0	45.55 ±20.18	M: 19 F: 13	pseudo-chilblain (+): 7	Feet (n=7)
Colonna et al, 2020 ²⁷	Skin lesion (+): 30 Skin lesion (-): 0	11±2.17	M: 17 F: 13	pseudo-chilblain (+): 30	Feet (n=26) Ankles (n=2) Hands (n=4)
De masson et al, 2020 ¹³	Skin lesion (+): 277 Skin lesion (-): 0	27	M: 129 F: 148	pseudo-chilblain (+): 106	Hands (n=23) Face (n=18)
Docampo simon et al, 2020 ¹⁴	Skin lesion (+): 58 Skin lesion (-): 0	14	M: 29 F: 29	pseudo-chilblain (+): 42	Hands (n=9) Feet (n=36) Hands and Feet (n=13)
Duong et al, 2020 ²⁸	Skin lesion (+): 295 Skin lesion (-): 0	N/A	N/A	pseudo-chilblain (+): 146	N/A
El Hachem et al, 2020 ²⁹	Skin lesion(+): 19 Skin lesion (-): 0	14±11.17	M: 14 F: 5	pseudo-chilblain (+): 19	Mostly on Toes, heels, and soles
Fernandez-nieto et al, 2020 ³⁰	Skin lesion(+): 132 Skin lesion (-): 214	19.9 ±1.56	M: 71 F: 61	pseudo-chilblain (+): 95	Hands (n=33) Feet (n=73)
Freeman et al, 2020 ³¹	Skin lesion(+): 505 Skin lesion (-): 0	25 ±17.38	M: 163 F: 155	pseudo-chilblain (+): 318	Feet (n= 267) Hands (n=15) Feet and Hands (n=36)

The Manifestations of Skin Lesion on COVID-19 Patients: A Systematic Review

Galvan, 2020 ¹⁶	Skin lesion (+): 375 Skin lesion (-): 0	55.3 ±20.2	M: 153 F: 222	pseudo-chilblain (+): 71	Mostly on hands and feet
Garcia-Lara et al, 2020 ³²	Skin lesion (+): 27 Skin lesion (-): 0	14.4	M: 18 F: 9	pseudo-chilblain (+): 25	Feet (n=18) Hands (n=7)
Gaspari et al, 2020 ²³	Skin lesion (+): 18 Skin lesion (-): 2	51	M: 17 F: 3	pseudo-chilblain (+): 6	Limbs (n=6)
Marzano et al, 2021 ¹⁸	Skin lesion (+): 200 Skin lesion (-): 0	40.25± 72.25	M: 108 F: 92	pseudo-chilblain (+): 46	Limbs (n=46)
Recalcati et al, 2020 ²⁴	Skin lesion (+): 14 Skin lesion (-): 0	14.4± 13.18	M: 6 F: 8	pseudo-chilblain (+): 14	Feet (n=8) Hands (n=4) Hands and feet (n=2)
Rubio-Muniz et al, 2020 ²⁰	Skin lesion (+): 34 Skin lesion (-): 0	54.5± 31.66	M: 14 F: 20	pseudo-chilblain (+): 9	Feet (n=9)

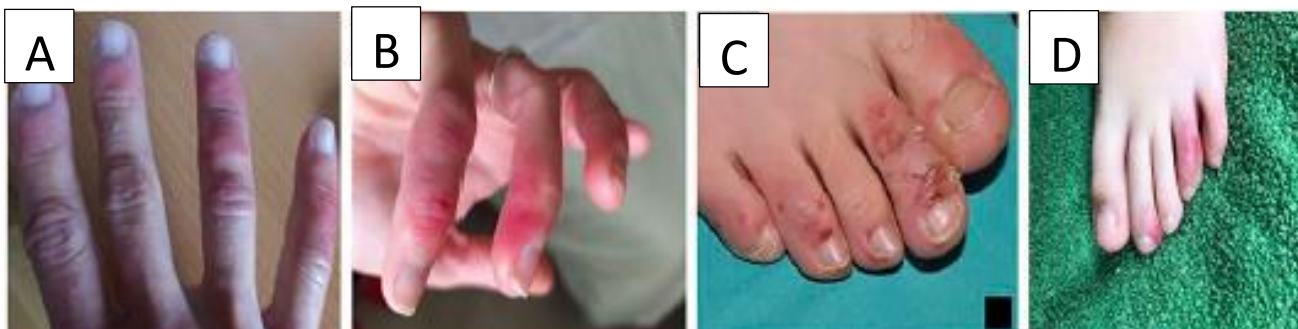

Figure 4. Image of pseudo-chilblain lesions in COVID-19 patients. (A), (B) Pseudo-chilblain located on the finger of patients. (C) Pseudochilbain lesion located on toes. (D) Pseudo-chilblain on the toes of pediatric patients.³⁰⁻³²

4. Vesicular

Vesicular is a skin condition in the form of lesions that resemble a sac filled with clear fluid under the epidermis layer. Another name for this lesion is a blister smaller than 1 cm in diameter, with many often appearing in clusters. The most common causes of vesicular lesions are heat conditions, contact dermatitis, drugs, autoimmune, or infection (bacteria or viruses). Examples of viral infections that exhibit vesicular lesions include varicella-zoster infection, herpes simplex, coxsackievirus, and echovirus.²⁵

The prevalence of vesicular lesions among COVID-19 patients who undergo cutaneous manifestations is not very common compared to other lesions mentioned earlier. From the results Table 4, only 4-15% of patients identified cutaneous manifestations with vesicular lesions. Various studies reported percentages ranging from 3.77% to 15%.¹⁶

This lesion commonly appears in middle-aged patients,^{9,13,30} contrast to the pseudochilbain lesion, typically for the location of vesicular lesions found on the trunk of the body,^{9,20,13,22,16,18,24,25} whereas a few numbers of these lesions were also identified on the extremities.^{9,22,16} The duration of cutaneous manifestations relative to other COVID-19 symptoms varied between the few studies reporting.³² Some studies stated that most vesicular lesions develop simultaneously as other systemic symptoms come; however, two studies from Italy reported that most of their lesions appear after COVID-19 symptoms.^{22,30} Galvan et al. showed the median latency times of vesicular lesions in 3 and 14 days.¹⁶ Prevalence of Vesicular lesions is thought to be associated with intermediate severity of COVID-19.³⁰

Several studies suggested some theories explain the mechanism of the occurrence of vesicular lesions. Fernando

The Manifestations of Skin Lesion on COVID-19 Patients: A Systematic Review

et al. stated that vesicular lesions are caused by the activation of the body's immune system in excessive amounts causing a "cytokine storm" involving the skin.³⁰ According to one study which demonstrated a direct cytopathic effect of SARS-CoV-2 on dermal endothelial vessels, it can produce vesicular lesions.^{30,32} Unlike maculopapular and urticarial lesions,

vesicular lesions associated with COVID-19 are considered etiologically unrelated to antiviral drugs or other COVID-19 treatments. Because of that, vesicular lesions have been described as "specific skin manifestations" of COVID-19, so their identification is potentially useful for diagnosis.³⁰

Table 4. Baseline Characteristic and further explanation of vesicular lesion in COVID-19 patients

Author, Year	Total Patients COVID-19	Mean Age (years)	Gender	Cutaneous Manifestations	Location cutaneous manifestations
Almeida et al, 2021 ⁹	Skin lesion (+): 45 Skin lesion (-): 0	37.2 ±19.68	M: 26 F: 19	Vesicular(+): 21	Trunk (n=15) limbs (n=7) Face (n=4)
Askin et al, 2020 ¹⁰	Skin lesion (+): 34 Skin lesion (-): 88	M: 57.44 ±17.259 F: 58.80 ± 15.918	M: 90 F: 32	Vesicular(+): 3	Trunk (n=3)
Bouaziz et al, 2020 ²¹	Skin lesion (+): 14 Skin lesion (-): 0	N/A	N/A	Vesicular(+): 2	N/A
De giorgi et al, 2020 ²²	Skin lesion (+): 53 Skin lesion (-): 625	55.9 ±28.69	M: 32 F: 21	Vesicular(+): 2	Trunk and Upper limbs (n=2)
De masson et al, 2020 ¹³	Skin lesion (+): 277 Skin lesion (-): 0	27	M: 129 F: 148	Vesicular(+): 41	Trunk and limbs (n=41)
Fernandez-nieto et al, 2020 ³⁰	Skin lesion(+): 132 Skin lesion (-): 214	19.9 ±1.56	M: 71 F: 61	Vesicular (+): 24	Head (n=4) Anterior Trunk (n=17) Posterior trunk (n=12) Arms (n=8) Legs (n=10) Palms/soles (n=2)
Galvan, 2020 ¹⁶	Skin lesion (+): 375 Skin lesion (-): 0	55.3 ±20.2	M: 153 F: 222	Vesicular(+): 34	Trunk and limbs (n=34)
Marzano et al, 2021 ¹⁸	Skin lesion (+): 200 Skin lesion (-): 0	40.25± 72.25	M: 108 F: 92	Vesicular (+): 29	Trunk (n=29)
Recalcati et al, 2020 ²⁴	Skin lesion (+): 18 Skin lesion (-): 70	N/A	N/A	Vesicular (+): 1	Trunk (n=1)
Yildiray et al, 2021 ²⁵	Skin lesion (+): 5 Skin lesion (-): 0	54.5± 31.66	M: 2 F: 3	Vesicular (+): 2	Trunk (n=2)

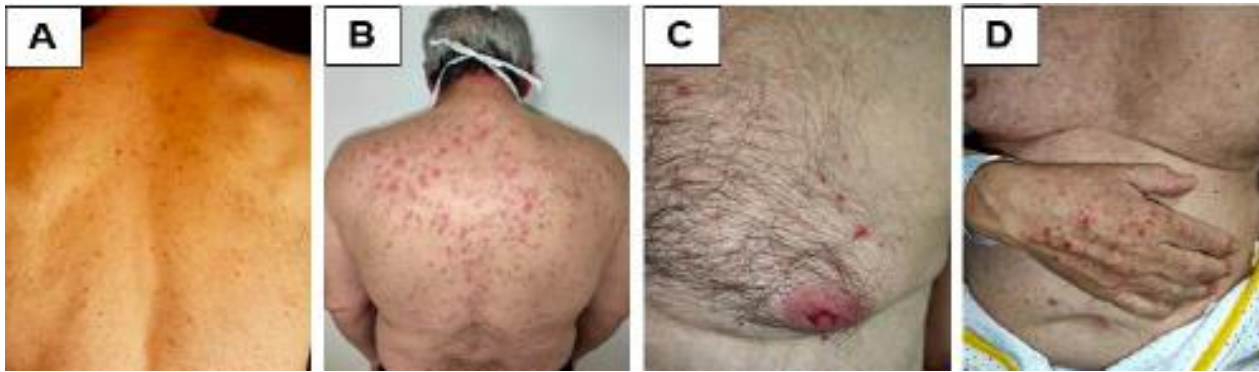

Figure 5. Image of Vesicular lesion in COVID-19 patients. (A) Vesicular lesions on trunk (monomorphic) (B) Vesicular lesions on trunk (Polymorphic) (C) Vesicular lesions scattered or clustered along the patient’s trunk. (D) located on the distal upper extremities (hands).

5. Petechiae/purpura

Petechiae is a skin lesion with characteristic small, non-blanching spots with a diameter of less than 2 mm. Petechiae are characterized as non-blanching because they do not disappear after a brief pressure is applied to the area of skin manifestation.^{16,18} When the non-blanching lesion is larger than 2 mm, it is called purpura.³⁰ Several causes of petechiae and purpura include “thrombocytopenia, platelet dysfunction, impaired coagulation, and loss of vascular integrity. The petechial rash is associated with several viral infections, including enterovirus, parvovirus B19 and dengue virus.^{10,18}

Petechiae/Purpura lesions are the less commonly cutaneous manifestations of COVID-19, almost similar to vesicular lesions. From the result table 5, 694 patients with skin lesions reported petechial/purpura patterns in only 3%-5% of patients (Table 5).^{9,10,21,11,13,14,18,20,33} The distribution of petechial/purpura lesions are varied diffusely, acral, or mostly on limbs.^{14,18,30,33} Some studies stated that petechial purpuric rash commonly found on distal extremities.¹⁶ De Giorgi et al. showed that diffuse petechiae and generalized palpable purpura usually appeared in cases with greater severity of infection.²² This statement was approved with the study in

Spain that provide the palpable purpura lesions, present in 4 of 34 cases (11.8%), were more frequent in middle-aged patients recovering from severe COVID-19 infections.^{18,30} Interestingly, a case series of 5 patients who developed respiratory failure due to severe COVID-19 infection had three patients exhibiting purpuric skin rash.²⁴

The study of Margo et al. stated that the pathophysiology for petechiae/purpura skin lesions involved “pauci-inflammatory thrombogenic vasculopathy”. Immunohistochemistry (IHC) showed extensive deposition of complement components C5b-9 and C4d in the cutaneous microvasculature of lesioned and non-lesional (normal-looking) skin. This complementary component is associated with the COVID-1953 spike glycoprotein.³³ Due to the severity of the COVID-19 cases seen with petechiae/purpura, alternative etiologies of the lesions may involve the adverse dermatological effects associated with potential COVID-19 drugs. Skin side effects of high-dose intravenous immunoglobulin (IVIG) treatment include petechiae, among many others. Purpura is an adverse skin effect of the possible anti-COVID-19 agent camostat mesylate.^{20,33} Finally, direct skin manifestations of SARS-CoV-2 could be possible, given that petechiae result from other viral infections.

Table 5. Baseline Characteristic and further explanation of petechiae/purpura lesions in COVID-19 patients

Author, Year	Total Patients COVID-19	Mean Age (years)	Gender	Cutaneous Manifestations	Location cutaneous manifestations
Almeida et al, 2021 ⁹	Skin lesion (+): 45 Skin lesion (-): 0	37.2 ±19.68	M: 26 F: 19	Petechiae/purpura(+): 6	Limbs (n=6) Generalized (n=2)
Askin et al, 2020 ¹⁰	Skin lesion (+): 34 Skin lesion (-): 88	M: 57.44 ±17.259 F: 58.80 ± 15.918	M: 90 F: 32	Petechiae/purpura(+): 4	distal limbs (n=3) Generalized (n=1)
Bouaziz et al, 2020 ²¹	Skin lesion (+): 14	N/A	N/A	Petechiae/purpura(+): 2	N/A

The Manifestations of Skin Lesion on COVID-19 Patients: A Systematic Review

	Skin lesion (-):	0			
Cerdeira et al, 2021 ¹¹	Skin lesion (+): 32	45.55 ±20.18	M: 19 F: 13	Petechiae/ purpura(+): 2	Limbs (n=2)
	Skin lesion (-):	0			
De masson et al, 2020 ¹³	Skin lesion (+): 277	27	M: 129 F: 148	Petechiae/ purpura(+): 7	Generalized (n=3) Limbs (n=4)
	Skin lesion (-):	0			
Docampo simon et al, 2020 ¹⁴	Skin lesion (+): 58	14	M: 29 F: 29	Petechiae/ purpura(+): 3	Hand and Feet (n=3)
	Skin lesion (-):	0			
Magro et al, 2021 ³³	Skin lesion (+): 200	40.25± 72.25	M: 108 F: 92	Petechiae/ purpura(+): 3	Limbs (n=3)
	Skin lesion (-):	0			
Marzano et al, 2021 ¹⁸	Skin lesion (+): 200	40.25± 72.25	M: 108 F: 92	Petechiae/ purpura(+): 13	Limbs (n=13)
	Skin lesion (-):	0			
Rubio-Muniz et al, 2020 ²⁰	Skin lesion (+): 34	54.5± 31.66	M: 14 F: 20	Petechiae/ purpura(+): 4	Lower limbs (n=4)
	Skin lesion (-):	0			

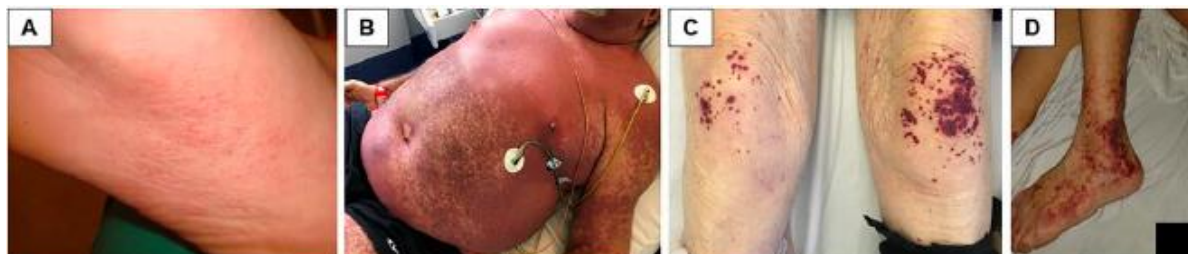


Figure 6. Image of petechiae/purpura lesions in COVID-19 patients. (A) Purpuric lesion on trunk (B), abdomen, and limbs (arm). (C) Purpuric lesions are present on the knees of the patient. (D) Palpable purpuric lesions located on the lower extremity of COVID-19 Patients.^{18,30,33}

6. Liveoid

Livedo reticularis (LR) is a transient or persistent skin manifestation characterized by a reticular (web-like, lace-like) pattern from reddish blue to purple-mottled discoloration.³⁴ These skin lesions occur due to cutaneous vascular disruption resulting in reduced blood flow and deoxygenated haemoglobin to the skin. Benign manifestations of liveoid eruptions that occur mainly due to physiological conditions (cutis marmorata) or are idiopathically referred to as LR.^{20,34} Livedoid eruptions that occur due to pathological conditions are called livedo racemosa (LRC). LRC is present as a permanent manifestation while showing a wider appearance on the body and a deformed/irregular shape compared to LR.^{9,34}

Livedoid eruptions are one of the least common cutaneous manifestations associated with COVID-19. From the result Table 6, 946 patients with skin lesions confirmed COVID-19 only 6 per cent of them presented with varying degrees of livedoid lesions.^{21,11,34,13,16,18,20} The location of these lesions including on the trunk, flexor surface of forearms, dorsal hand and dorsal foot,^{21,11,34,13,16,18,20} mostly common on the trunk.^{21,11,13,16,18,20} These lesions occurred simultaneously with other Covid-19 symptoms and primarily appeared in elderly patients with more severe infections.^{11,16,20} The onset of this lesion was 9.4 days on average. The highest mortality rate of cutaneous lesions among patients associated with covid-19 is livedoid lesion compared to another lesion already mentioned above.³⁴

The Manifestations of Skin Lesion on COVID-19 Patients: A Systematic Review

The pathophysiology of livedoid lesions is still unclear. However, one theory suggests a hypercoagulable relationship with Covid-19 infection.³⁴ A retrospective study of 183 patients with Covid-19 showed that non-survivors of the study had higher levels of D-dimer and fibrin degradation products in addition to a longer prothrombin time, indicating

that patients with severe COVID-19, similar to those with livedoid. This may pose a greater risk for coagulation disorders.^{20,30,34} Other studies have also suggested that disseminated intravascular coagulation (DIC) and macro thrombosis may be associated with the production of livedo reticularis in more severe cases of infection.³⁴

Table 6. Baseline Characteristic and further explanation of livedoid lesions in COVID-19 patients

Author, Year	Total Patients COVID-19	Mean Age (years)	Gender	Cutaneous Manifestations	Location cutaneous manifestations
Bouaziz et al, 2020 ²¹	Skin lesion (+): 14 Skin lesion (-): 0	N/A	N/A	Livedoid (+): 1	Trunk (n=1)
Cordeira et al, 2021 ¹¹	Skin lesion (+): 32 Skin lesion (-): 0	45.55 ±20.18	M: 19 F: 13	Livedoid (+): 4	Trunk (n=4)
Cordoro et al, 2020 ³⁴	Skin lesion (+): 13 Skin lesion (-): 89	39.3 ±17.9	M: 95 F: 7	Livedoid (+): 3	Upper and lower limbs (n=3)
De masson et al, 2020 ¹³	Skin lesion (+): 277 Skin lesion (-): 0	27	M: 129 F: 148	Livedoid (+): 4	Trunk and limbs (n=4)
Galvan, 2020 ¹⁶	Skin lesion (+): 375 Skin lesion (-): 0	55.3 ±20.2	M: 153 F: 222	Livedoid(+): 21	Trunk (n=21) Limbs (n=7)
Marzano et al, 2021 ¹⁸	Skin lesion (+): 200 Skin lesion (-): 0	40.25± 72.25	M: 108 F: 92	Livedoid(+): 4	Trunk and limbs (n=4)
Rubio-Muniz et al, 2020 ²⁰	Skin lesion (+): 34 Skin lesion (-): 0	54.5± 31.66	M: 14 F: 20	Livedoid(+): 1	Trunk (n=1)

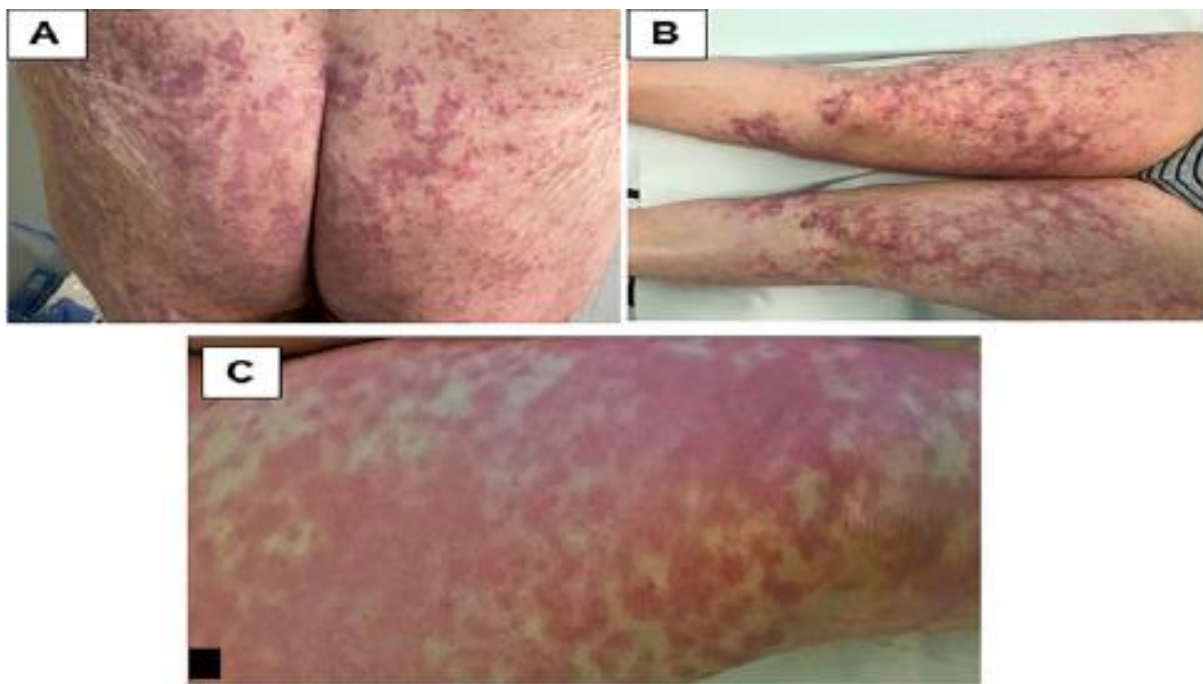


Figure 7. Image of livedoid lesions in COVID-19 patients. (A) Livedoid lesions on the patient's buttocks. (B) Lesions affecting the patient's lower extremities (thighs) are livedo racemose-like. (C) Livedoid eruption is present in an intubated patient with severe systemic and pulmonary symptoms associated with COVID-19.^{16,18,20}

IV. DISCUSSION

The COVID-19 pandemic, which continues today, is associated with SARS-CoV-2 infection in humans, resulting in an ongoing global health crisis. Many studies are being done massively worldwide, with new information being published daily; However, the clinical characteristics of COVID-19, including its skin manifestations, are still unknown. Several viruses that attack the respiratory system have been associated with skin manifestations in the past; the lesions caused by SARS-CoV-2 are unlike previous lesions; this is because other members of the coronavirus family, such as SARS-CoV and MERS-CoV, do not show any skin of lesions occurs.³⁴ Recent literature stated that the skin manifestations of COVID-19 are divided into two categories, namely inflammatory (maculopapular/morbilliform, urticaria, vesicular) or vascular lesions (e.g. chilblain, petechiae/purpura, and lived) lesions.^{6,16} The knowledge of skin lesions related to COVID-19 infection is a very important role for doctors to assist in diagnosing and treating COVID-19 patients in the future.⁹

Based on the results (table 1-6), six patterns of skin lesions occur in the presence of COVID-19 infection, including maculopapular lesions, urticaria, pseudo-chilblain, vesicular, petechiae/purpura and livedoid. Among these skin lesions, maculopapular and pseudo-chilblains lesions appear to be the most common, followed by urticarial, vesicular, livedoid, and petechial/purpura rash. Maculopapular skin lesions and urticaria are commonly seen in middle-aged to older patients and are usually associated with severe COVID-19 infection. Both rash onsets varied between studies and were reported to be unhelpful in the diagnosis due to possible drug-induced dermatological adverse reactions. Before the

systemic symptoms of COVID-19 appear, vesicular lesions are often present. This exanthema, common in middle-aged patients, is commonly seen in viral infections such as varicella-zoster and herpes simplex.

The types of vascular skin lesions associated with COVID-19 consisted of pseudo-chilblain, livedoid, and petechiae/purpura. Pseudo-chilblain lesions are similar to pernio lesions caused by exposure to cold temperatures, but pseudo-chilblains occur in warmer climates. The typical characteristics of pseudochilblain lesions usually occur in children to young adults, with the most common location in the distal extremities, especially the patient's fingers and toes and is associated with less severe COVID-19 infection. These lesions, occurring after the systemic symptoms of COVID-19 occur, differ from vesicular lesions. Both livedoid and petechiae/purpura lesions were less frequent in COVID-19 patients than the other four lesions mentioned earlier. Livedoid lesions are often seen in elderly patients with severe COVID-19 infection. Consistent with petechiae/purpuric lesions, which are also more common in middle-aged patients with greater severity of COVID-19 infection. These two lesions are most commonly found throughout the body (diffuse), acral, or distal extremities. The mortality rate for vascular lesions is the highest compared to other skin manifestations, costing 10 per cent.^{17,30}

The pathophysiological mechanism of skin manifestations associated with COVID-19 is still unclear, but many theories have been considered. Several theories suggest that adverse reactions to COVID-19 pharmaceutical drugs or hyperinflammation-induced overproduction of cytokines cause maculopapular and urticarial skin lesions.³ The possible molecular mechanisms of chilblain-like lesions include

The Manifestations of Skin Lesion on COVID-19 Patients: A Systematic Review

“immune dysregulation, vasculitis, vascular thrombosis or neoangiogenesis.^{5,6} The pathogenesis for petechial/purpuric skin lesions involves a pause-inflammatory thrombogenic vasculopathy with extensive deposition of complement components C5b-9 and C4d in the cutaneous microvasculature of both lesional and non-lesional skin. An alternative aetiology of these skin lesions could be adverse dermatological side effects from COVID-19 drugs.^{16,30} The mechanism of livedoid skin lesions is seen from the severity of COVID-19 infection. In severe infections, lived lesions are usually caused by disseminated intravascular coagulation (DIC) and macrothrombosis. However, in less severe COVID-19 infections, these vascular lesions are thought to be the product of microthrombus formation created by inflammatory cytokines or entry of ACE2 into cells.²⁵⁻²⁸ Pada Lesi vesikular merupakan hasil dari "badai sitokin" yang diakibatkan oleh aktivasi yang berlebihan dari sistem kekebalan tubuh.¹⁶

V. CONCLUSION

In conclusion, the Sars-Cov-2 virus spreads silently, mainly to asymptomatic carriers; an accurate and rapid identification for cutaneous manifestations could be a vital strategy for early diagnosis and leads to a likely better prognosis in COVID-19 patients. This systematic review supplied a complex and detailed analysis of 6 central dermatology patterns that are common in COVID-19 patients, such as maculopapular/morbilloform, urticaria, vesicular, chilblain-like/pseudo-chilblain, petechiae/purpura, and lived and explained the underlying molecular mechanisms. Another future study on cutaneous manifestations related to COVID-19 is still needed for detailed analysis.

REFERENCES

- I. Guo YR, Cao QD, Hong ZS, et al. The origin, transmission and clinical therapies on coronavirus disease 2019 (COVID-19) outbreak -an update on the status. *Mil Med Res*. Mar 13 2020;7(1):11
- II. Abouhashem AS, Singh K, Azzazy HME, Sen CK. Is Low Alveolar Type II Cell SOD3 in the Lungs of Elderly Linked to the Observed Severity of COVID-19? *Antioxid Redox Signal*. Jul 10 2020;33(2):59-65.
- III. Wang C, Worswick S. Cutaneous manifestations of COVID-19. *Dermatology Online Journal*. 2021;27(1).
- IV. Molaee, H., Allahyari, F., Emadi, S. N., Radfar, S., & Razavi, Z. (2021). Cutaneous manifestations related to the COVID-19 pandemic: a review article. *Cutaneous and Ocular Toxicology*, 40(2), 168–174.
- V. Guervilly C, Bonifay A, Burtey S, et al. Dissemination of extreme levels of extracellular vesicles: tissue factor activity in patients with severe COVID-19. *Blood Adv* 2021;5:628–634.
- VI. Rongioletti F, Ferreli C, Sena P, Caputo V, Atzori L. Clinicopathologic correlations of COVID-19-related

cutaneous manifestations with special emphasis on histopathologic patterns. *Clinics in Dermatology*. 2021;39(1):149-162.

- VII. Xue X, Mi Z, Wang Z, Pang Z, Liu H, Zhang F. High Expression of ACE2 on Keratinocytes Reveals Skin as a Potential Target for SARS-CoV-2. *J Invest Dermatol*. May 23 2020.
- VIII. Guan WJ, Ni ZY, Hu Y, et al. Clinical Characteristics of Coronavirus Disease 2019 in China. *N Engl J Med*. Apr 30 2020;382(18):1708-1720.
- IX. Almeida G, Arruda S, Marques E, Michalany N, Sadick N. Presentation and Management of Cutaneous Manifestations of COVID-19. *Journal of Drugs in Dermatology*. 2020;20(1):76-83.
- X. Askin O, Altunkalem RN, Altinisik DD, Uzuncakmak TK, Tursen U, Kutlubay Z. Cutaneous manifestations in hospitalized patients diagnosed as COVID-19. *Dermatol Ther*. Jun 24 2020.
- XI. Rodriguez-Cerdeira C, Uribe-Camacho B, Silverio-Carrasco L, Méndez W, Mahesh A, Tejada A et al. Cutaneous Manifestations in COVID-19: Report on 31 Cases from Five Countries. *Biology*. 2021;10(1):54.
- XII. Dalal A, Jakhar D, Agarwal V, Beniwal R. Dermatological findings in SARS-CoV-2 positive patients: An observational study from North India. *Dermatol Ther*. Jun 16 2020:e13849.
- XIII. De Masson A, Bouaziz JD, Sulimovic L, et al. Chilblains is a common cutaneous finding during the COVID-19 pandemic: A retrospective nationwide study from France. *J Am Acad Dermatol*. May 4 2020.
- XIV. Docampo-Simón A, Sánchez-Pujol MJ, Juan-Carpena G, et al. Are chilblain-like acral skin lesions really indicative of COVID-19? A prospective study and literature review. *J Eur Acad Dermatol Venereol*. May 26 2020.
- XV. Fattori A, Cribier B, Chenard M, Mitcov M, Mayeur S, Weingertner N. Cutaneous manifestations in patients with coronavirus disease 2019: clinical and histological findings. *Human Pathology*. 2021;107:39-45.
- XVI. Galván Casas C, Català A, Carretero Hernández G, et al. Classification of the cutaneous manifestations of COVID-19: a rapid prospective nationwide consensus study in Spain with 375 cases. *Br J Dermatol*. Jul 2020;183(1):71-77.
- XVII. Herrero-Moyano M, Capusan TM, Andreu-Barasoain M, et al. A clinicopathological study of eight patients with COVID-19 pneumonia and a late-onset exanthema. *J Eur Acad Dermatol Venereol*. May 19 2020.
- XVIII. Marzano A, Genovese G, Moltrasio C, Gaspari V, Vezzoli P, Maione V et al. The clinical spectrum of COVID-19-associated cutaneous manifestations: An

The Manifestations of Skin Lesion on COVID-19 Patients: A Systematic Review

- Italian multicenter study of 200 adult patients. *Journal of the American Academy of Dermatology*. 2021;84(5):1356-1363.
- XIX. Reymundo A, Fernández-Bernáldez A, Reolid A, et al. Clinical and histological characterization of late appearance maculopapular eruptions in association with the coronavirus disease 2019. A case series of seven patients. *J Eur Acad Dermatol Venereol*. Jun 4 2020.
- XX. Rubio-Muniz CA, Puerta-Peña M, Falkenhain-López D, et al. The broad spectrum of dermatological manifestations in COVID-19: clinical and histopathological features learned from a series of 34 cases. *J Eur Acad Dermatol Venereol*. Jun 11 2020.
- XXI. Bouaziz JD, Duong T, Jachiet M, et al. Vascular skin symptoms in COVID-19: a french observational study. *J Eur Acad Dermatol Venereol*. Apr 27 2020.
- XXII. De Giorgi V, Recalcati S, Jia Z, et al. Cutaneous manifestations related to coronavirus disease 2019 (COVID-19): A prospective study from China and Italy. *J Am Acad Dermatol*. May 19 2020.
- XXIII. Gaspari V, Neri I, Misciali C, Patrizi A. COVID-19: how it can look on the skin. Clinical and pathological features in 20 COVID-19 patients observed in Bologna, north-eastern Italy. *J Eur Acad Dermatol Venereol*. Jun 3 2020.
- XXIV. Recalcati S. Cutaneous manifestations in COVID-19: a first perspective. *J Eur Acad Dermatol Venereol*. May 2020;34(5):e212-e213.
- XXV. Yildiray Y, Ayse P. Cutaneous manifestations of coronavirus disease in Turkey: A prospective study. *Dermatologica Sinica*. 2021;39(2):74.
- XXVI. Andina D, Noguera-Morel L, Bascuas-Arribas M, et al. Chilblains in children in the setting of COVID-19 pandemic. *Pediatr Dermatol*. May 2020;37(3):406-411
- XXVII. Colonna C, Genovese G, Monzani NA, et al. Outbreak of chilblain-like acral lesions in children in the metropolitan area of Milan, Italy, during the COVID-19 pandemic. *J Am Acad Dermatol*. Jun 10 2020.
- XXVIII. Duong TA, Velter C, Rybojad M, et al. Did Whatsapp((R)) reveal a new cutaneous COVID-19 manifestation? *J Eur Acad Dermatol Venereol*. Apr 24 2020.
- XXIX. El Hachem M, Diociaiuti A, Concato C, et al. A clinical, histopathological and laboratory study of 19 consecutive Italian paediatric patients with chilblain-like lesions: lights and shadows on the relationship with COVID-19 infection. *J Eur Acad Dermatol Venereol*. May 31 2020.
- XXX. Fernandez-Nieto D, Jimenez-Cauhe J, Suarez-Valle A, et al. Characterization of acute acral skin lesions in nonhospitalized patients: A case series of 132 patients during the COVID-19 outbreak. *J Am Acad Dermatol*. Jul 2020;83(1):e61-e63.
- XXXI. Freeman EE, McMahon DE, Lipoff JB, et al. Pernio-like skin lesions associated with COVID-19: a case series of 318 patients from 8 countries. *J Am Acad Dermatol*. May 29 2020.
- XXXII. Garcia-Lara G, Linares-González L, Ródenas-Herranz T, Ruiz-Villaverde R. Chilblain-like lesions in pediatrics dermatological outpatients during the COVID-19 outbreak. *Dermatol Ther*. May 6 2020:e13516.
- XXXIII. Magro C, Mulvey JJ, Berlin D, et al. Complement associated microvascular injury and thrombosis in the pathogenesis of severe COVID-19 infection: A report of five cases. *Transl Res*. Jun 2020;220:1-13.
- XXXIV. Cordoro KM, Reynolds SD, Wattier R, McCalmont TH. Clustered cases of acral perniosis: Clinical features, histopathology, and relationship to COVID-19. *Pediatr Dermatol*. May 2020;37(3):419-423.