

Control of Acute Pain in a Patient with Acute Chronic Low Back Pain by Using Ecoguided Facetory Analgesic Block in the Emergency Room, Report of Two Cases

Dr. Israel Morales Garcia¹, Dr. Gibran Guadalupe Sanchez Salas²

¹Emergenciólogist / Master In Pain General Hospital Zone #2 Imss, Hermosillo, Sonora, Mexico

²3rd Year Resident of Medical Surgical Emergencies General Hospital Zone #2 Hermosillo, Sonora, Mexico

ABSTRACT

Low back pain is one of the most frequent causes of disability, it is a problem that is characterized by its high prevalence in the population and its economic and social repercussions, becoming one of the main causes of work absenteeism. In this entity, there is an association between muscular and psychosocial factors that generate avoidance behaviors, fear and muscle atrophy, causing a vicious circle that favors chronicity and disability. The prevalence of this syndrome is 60-85% during the survival of individuals. Between 15 and 20% of adults suffer from low back pain; in 90% of cases it is non-specific, it affects both men and women, and occurs more in ages between 30 and 50 years; increasing prevalence with age. The most important challenge in the diagnosis of low back pain is to differentiate the 95% whose origin is benign musculoskeletal processes, from the 5% whose low back pain is caused by specific diseases that require rapid and adequate treatment. In this task, the warning signs that help to rule out the most serious processes can be useful. The warning signs in low back pain are: age >50 years, history of neoplasia, constitutional syndrome, no improvement with usual treatments, pain at rest, fever, immunosuppression, previous trauma, osteoporosis, taking corticosteroids and cauda equina syndrome. It should also be noted that in approximately 80% of cases it will not be possible to arrive at a specific diagnosis. Thanks to advances in imaging, neural anatomical findings, new discoveries in the chemical mediation of pain, the development of ultrasound-guided injection techniques, we have greater diagnostic and therapeutic accuracy, and the highest success rate in non-surgical treatments have facilitated the expansion of minimally invasive techniques in pain management. On this occasion, two patients with pain at the level of the intense lumbar region are presented, who were managed with opioid analgesics, NSAIDs without pain improvement, in both cases ultrasound-guided fascetarian blocks were applied, with pain remission on a VAS scale of 10 /10 to 1/10, being discharged from the service.

KEYWORDS: low back pain, facet syndrome, facet block, ultrasound, emergency.

ARTICLE DETAILS

Published On:
02 November 2023

Available on:
<https://ijmscr.org/>

INTRODUCTION

Low back pain is one of the most frequent causes of disability, it is a problem that is characterized by its high prevalence in the population and its economic and social repercussions, becoming one of the main causes of work absenteeism. An association is produced between muscular and psychosocial factors that generate avoidance behaviors, fear and muscular atrophy, causing a vicious circle that favors chronification and disability. The prevalence of this syndrome is 60-85% during the survival of individuals. Between 15 and 20% of adults suffer from low back pain: in 90% of cases it is non-specific and occurs at all ages. Pain in low back pain can

originate in the intervertebral disc, facet joint, sacroiliac joint, vertebral periosteum, muscles, blood vessels, fascia, nerves, meninges, there is a great challenge in the diagnosis of low back pain, which is to differentiate 90% whose origin is benign musculoskeletal processes, 10% is produced by a specific disease such as those mentioned above(1).

Utilizing the limited resources available at an early point in time can prevent the development of unnecessary suffering and related costs. Various approaches to the prevention of back pain have been reported in the literature, but there is still a lack of clarity regarding which Prevention of the onset of low back pain and prevention of chronic low back pain and

Control of Acute Pain in a Patient with Acute Chronic Low Back Pain by Using Ecoguided Facetary Analgesic Block in the Emergency Room, Report Of Two Cases

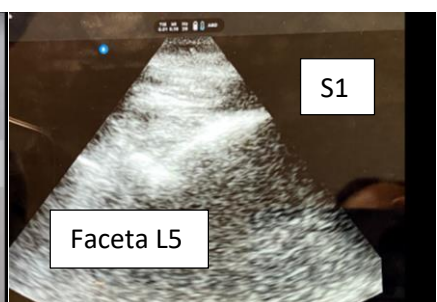
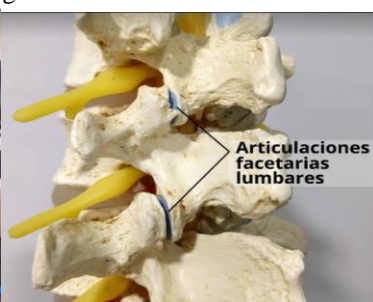
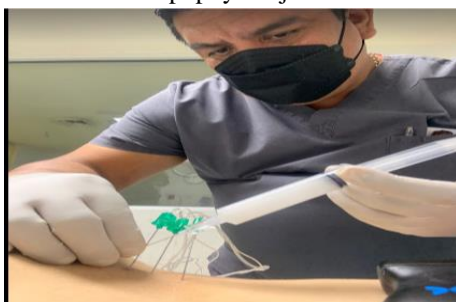disability are major challenges in non-specific low back pain. it represents a large majority of cases (Deyo and Weinstein 2001) and there is great variability in its clinical management. Low back pain is most commonly treated in primary health care settings. The diagnosis and therapeutic management of patients with acute pain as well as chronic low back pain appear to vary substantially between healthcare providers (eg general practitioners, specialist physicians, physiotherapists, chiropractors, osteopaths) within European countries. However, there are also considerable discrepancies in the management of low back pain between countries in the European region and Mexico is no exception, so it is necessary to increase consistency in the management of the approach and treatment of back pain between professions and countries. . The field of low back pain research in primary care is an excellent example of evidence-based health care; emergency services are the recipients of these patients in exacerbation of this condition. (2). The estimated point prevalence of non-specific low back pain is 18%. Annually, the total costs of low back pain are estimated at US\$100 billion in the US, €3.5 billion in the Netherlands, €6.6 billion in Switzerland, €17.4 billion in Germany and US\$9.17 billion in Australia. Although low back pain imposes a huge economic burden on health systems, this condition is responsible for affecting people's daily lives. Therefore, effective strategies play an important role in minimizing the Impact of low back pain. Clinical practice guidelines provide evidence-based recommendations to aid in decision-making about health interventions. (3)

The vertebral interapophyseal joint can be the cause of low back pain with mechanical characteristics, fundamentally secondary to a degenerative process. The characteristics of low back pain of facet origin are also common to other etiologies of pain, such as low back pain that radiates to the buttocks, groin or hips or in non-specific forms over the lower limbs but never to the feet: pain that increases with standing and sitting prolonged, tenderness on palpation of the facet joints, decreased lumbar mobility in all planes, especially lumbar extension and rotation, and a negative neurological examination and valsalva. The ASIPP (American Society of Interventional Pain Physician) recommends the use of diagnostic block, under visual control, in patients with clinical suspicion of low back pain of facet origin. (4). The blockade of the interapophysial joint has as a diagnostic and

therapeutic objective, since it will determine with its effectiveness, if the facet syndrome is the fundamental cause of the pain that the patient presents, the blockade has been defined as a simple and safe technique, which It can be performed under direct vision with the use of ultrasound. Infiltration with steroids in lumbar facet syndrome is effective in the short term, making it a complementary tool for multimodal management in the emergency room (5,6).

CASE 1

This is a 33-year-old male patient, who was admitted to the emergency department with pain in the lumbar region with radiation to the left pelvic limb, denies chronic diseases, denies allergies to medications. He mentions that his current condition began on January 18, 2022, when he was playing American football, he suffered a direct contusion to his back when being tackled, after that he began with pain that was controlled with common analgesics, an X-ray of the lumbar spine was performed without evidence of alterations In other words, at that time, on January 26, he returned to the emergency room due to exacerbation of pain, on this occasion he mentioned irradiation to the left pelvic limb with a sensation of paresthesia towards the same extremity, on this occasion analgesics and muscle relaxants were applied, without improvement due to which is decided on the application of bilateral facet block at the level of L4-L5-S1 with 7.5% ropivacaine 150 mg + 40 mg of methylprednisolone acetate + saline solution for a total volume of 30 ml which are distributed in 15 ml per each side (5ml for each articular facet) The procedure is performed in a shock room for monitoring and the patient is placed in ventral decubitus, asepsis and antisepsis of the lumbar region is performed, it is performed with ultrasound guidance, the aforementioned articular facets are identified, it is performed procedure out of plane, needles are introduced observing that it reaches the facet joint at the same time reproducing the pain and 5 ml of the aforementioned medicament preparation is administered, with which the pain improves, which on the eva scale 9/10 before the eva block 1/10 after the block, when the pain improves, the patient is sent for imaging studies, an MRI is performed where a bilateral posterocentral and posterolateral hernia is reported, predominantly left, L4-L5, decreased bilateral amplitude with tear of the fibrous ring , decrease of the lumbar canal

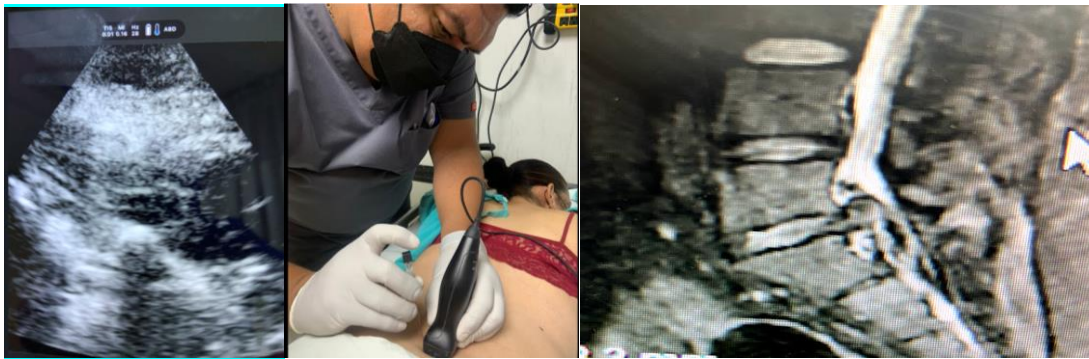

CASE 2

Control of Acute Pain in a Patient with Acute Chronic Low Back Pain by Using Echoguided Facetory Analgesic Block in the Emergency Room, Report Of Two Cases

A 44-year-old female who was admitted to the emergency department with disabling pain in the lumbar region with radiation to both pelvic limbs, with several admissions prior to the service, in which she was controlled with NSAIDs and muscle relaxants without any improvement, for which In his last admission after a physical examination, facet syndrome was diagnosed, for which an analgesic block was proposed, which with prior informed consent, an ultrasound-guided block was performed at the L4-L5 level with ropivacaine

7.5% 100mg + methylprednisolone acetate 40mg in volume. of 20 ml, 5 ml was applied bilaterally at each mentioned level, EVA on admission 10/10 prior to the block, after the EVA block 3/10, which improves mobility and can be discharged from the service to continue its evaluation by the neurosurgery service, where after performing a lumbar MRI, she was diagnosed with a hernia at the level of L4-L5 extruded with compression towards both foramina and the medullary canal.



DISCUSSION

Admissions for pain in the emergency services reach percentages of up to 80%, of which approximately 65% is derived from some trauma or muscle injury, low back pain falls within these statistics, pain management in the emergency room registers oligoanalgesia, or a limited availability of analgesics in the public physician, which forces us to seek alternatives for pain management in these patients, the introduction of technology in the area of medicine does not open up an important range of resources that we can apply in emergency services, the introduction of ultrasound in critical areas, and the use of this tool to carry out invasive procedures makes it safer and with a reduction in complications inherent to the procedure, ultrasound-guided regional analgesia has been present above all in the countries where due to epidemics such as heroin and currently fentanyl, the opportunity to control pain through multimodal analgesia was seen, using echoguided and NSAID nerve blocks, leaving aside morphinics. With which good results have been observed, the Facet analgesic blocks have shown good acceptance and good results when applied to acute low back pain, giving opportunity for timely evaluations and evaluations by algologists, neurosurgeons and orthopedists for the definitive management of the conditions that have triggered this painful process. In the case of our patients, the analgesic block gave a margin of time so that the necessary imaging studies could be carried out in order to have an accurate diagnosis and carry out the definitive pain control planning, which in the case of patient number 1 was He underwent thermal bicuplasty with a refrigerated radiofrequency system, as well as thermal foraminal and facet blocks. In the case of patient number 2, she underwent surgery for excision of herniated disc.

CONCLUSION

Within the capacities that the emergency doctor must have is the adequate management of pain and this is through adequate knowledge of analgesics and their adjuvants, but it is equally important to have alternatives for pain management such as analgesia. regional ultrasound-guided, since having adequate pain management we reduce the deleterious effects that are generated, such as insomnia, hypertension, increased muscle tone that leads to greater oxygen consumption and consequently ischemia, we also reduce the chronification of pain, For this reason, it is important to have the availability and collaboration of all the doctors who manage pain to train emergency physicians in this important tool, since adequate pain control generates good quality of care and satisfaction in our patients, which are indicators of quality in medical care.

REFERENCES

- I. Low back pain: causes, diagnosis and management, Chavarria, rev. Med. From Costa Rica and Central America LXXI (611) 447-454, 2014
- II. European guidelines for the management of low back pain, *acta arthop scand (suppl 305)* 2002;73
- III. Clinical practice guidelines for the management of non-specific low back pain in primary care: an updated overview, *European spine journal* (2018) 27-2791-2803
- IV. Minimally invasive techniques in the treatment of chronic pain, J.Medel Rebollo et al/*semin fund esp rheumatol.* 2013;14(4);135-141
- V. Interventional approach to lumbar facet syndrome: radiofrequency denervation, Martinez-Martinez, et al. rev. *Chilean Radiology* Vol. 23 No. 1, year 2017;7-14.

Control of Acute Pain in a Patient with Acute Chronic Low Back Pain by Using Ecoguided Facetary Analgesic Block in the Emergency Room, Report Of Two Cases

- VI. Review of corticosteroid treatment in back pain according to evidence-based medicine. F. Neira et al. *Rev. Soc. Esp Pain.* 2009; 16(6):352-369.