

Gist Tumor Manifested with Digestive Tract Bleeding: Case Report and Literature Review

Rodolfo Martín Ruiz Ravelo¹, José de Jesús Fernández Rivera¹, Marcela Molinar Lechuga¹, Perla Karina Hernández De Lira¹, Nancy Jaime Toledo²

¹ Mexican Social Security Institute – General Hospital of Zone No. 33. Department of Internal Medicine. Monterrey, Nuevo León, México

² University of Guadalajara. General Medicine. Guadalajara, Jalisco, México.

ABSTRACT

Gastrointestinal stromal tumors are known as the most common mesenchymal neoplasms, however they only represent less than 3% of malignant gastrointestinal neoplasms. Its symptoms, biochemical evaluation and imaging diagnosis are variable and non-specific and depends on the location and size of the tumor at the time of diagnosis, the histopathological and immunohistochemical analysis are necessary for a certain diagnosis at 95% in the most of cases. These tumors express tyrosine kinase activity, so if complete tumor resection is not possible or in those tumors with a high risk of recurrence, management with tyrosine kinase inhibitors (imatinib) may be indicated, which has significantly improved the prognosis of the disease.

KEYWORDS: Gastrointestinal stromal tumor, Gastrointestinal neoplasms, Imatinib, Mesenchymal neoplasms, Tyrosine kinase.

ARTICLE DETAILS

Published On:
28 October 2023

Available on:
<https://ijmscr.org/>

INTRODUCTION

Gastrointestinal stromal tumors (GIST) are a subgroup of mesenchymal tumors that origins from soft tissues and have their primary origin in the interstitial Cajal cells [1]. Despite being known as the most common mesenchymal neoplasms of the digestive tract, they only represent between 1-3% of malignant gastrointestinal neoplasms [2].

This type of tumors usually affect the gastrointestinal tract in most cases (80%), with the stomach as the most frequent location, followed by duodenum, jejunum, colon and rectum [3]; Less frequently occurs outside the gastrointestinal tract, being the mesentery and retroperitoneum the most frequent sites of presentation [4].

The clinical picture, laboratory and image studies similarly to the majority of gastrointestinal tumors are not specific, so the final diagnosis falls on histopathological analysis by biopsy, which must be obtained with special care due to the risk of rupture of the tumor capsule and consequently the tumoral dissemination.

Of special importance is the association with the oncogenic mutation in the KIT gene, which is regulated by tyrosine kinase activity. In tumors unresectables, tyrosine kinase

inhibitors such as imatinib have an important role in the treatment because they significantly improved the prognosis in the last years, before they being integrated into the treatment the mortality in unresectable tumors was very high.

Hence the importance of and adequate suspected diagnosis and timely treatment that is the principal point to treat in this review so we will comment key points to improve the survival of GIST.

CASE REPORT

We present a case of a 48-year-old male with no chronic degenerative diseases or personal pathological history of importance for the current condition who reports that his condition began a month prior to his admission with presence of a feeling of early progressive satiety, asthenia and anorexia with subsequent appearance of evacuations with melanic characteristics in a small quantity which subsided spontaneously, however after the recurrence of the evacuations in greater quantity, additionally to disabling asthenia and adynamia, he went to the emergency department of our hospital being admitted without clinical

Gist Tumor Manifested with Digestive Tract Bleeding: Case Report and Literature Review

signs of hemodynamic instability, vital signs within normal parameters, during his initial evaluation the following laboratories were performed:

TP 13.1s, INR 1.1, TPT 24.3s, Leukocytes 7.1k/UI, Hemoglobin 5.5 g/dL, Hematocrit 20.8% V.C.M. 93.7%, H.C.M. 24.8, Platelets 370k/IU, ALT 23.1 U/L AST 19.3 U/L BD 0.23 mg/dL BI 0.41 mg/dL BT 0.64 mg/dL. Due to the hemoglobin value a transfusion of 2 erythrocyte concentrates was required and upper endoscopy were performed, in which at the minor gastric curvature a tumor with exophytic characteristics were observed, approximately of 40mm of diameter with an apical erosion and visible vessel (Fig 1).

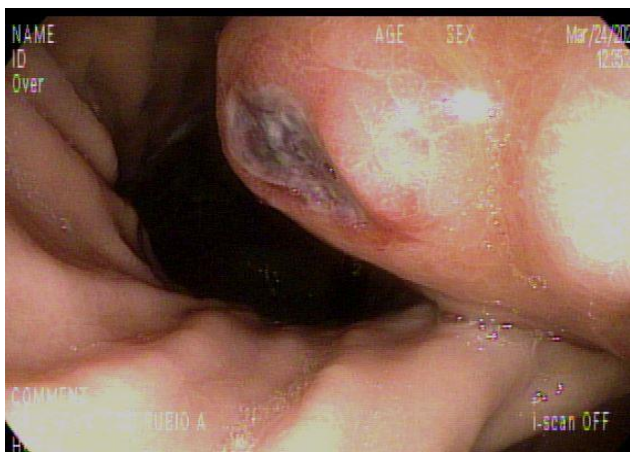

Figure 1. Upper endoscopy showing an exophytic tumor with central ulceration at the level of the lesser gastric curvature.

Adjacent to this main lesion, another elevated and ulcerated area with fibrin and raised borders were observed, the rest of the gastric mucosa were seen without alterations. Biopsies of the lesion were not taken due to having a visible central vessel and due to suspicion of a GIST submucosal tumor by macroscopic characteristics, in order to avoid tumor dissemination due to the friability that these lesions may have. Therefore, as part of the diagnostic extension protocol of said tumor, a simple and contrasted thoracoabdominal computed tomography (CT) was requested, revealing a collapsed stomach, which was difficult to assess, with an internal irregular lesion, with lobulated edges, isodense with apparently heterogeneous reinforcement dependent on the stomach lower wall and projecting towards lumen, with approximate measurements in the axial plane of 5.2 x 4.8 cm (Fig 2) suggestive of a neo-formative process, tumor lesions on peripheral lymph nodes were not detected.

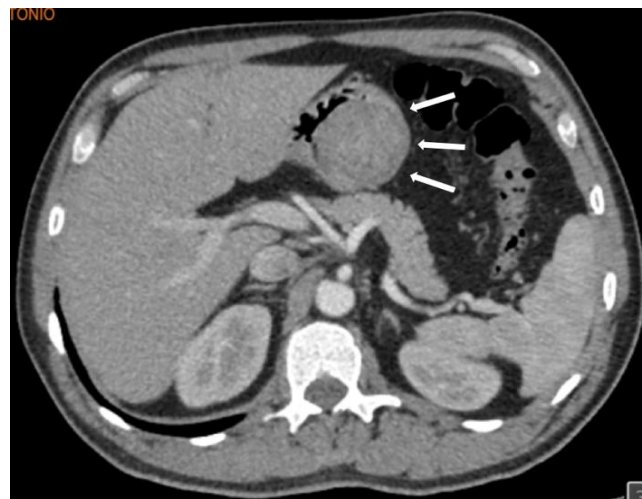


Figure 2. Contrast-enhanced abdominal tomography, we observed an intragastric tumor that tends to occlude practically all of gastric lumen (Arrows) .

Due to the impossibility to take biopsy by endoscopy, surgical treatment was decided by the surgical oncology service, performing Subtotal gastrectomy + Roux-en-Y gastrojejunostomy, obtaining a 4x4 cm tumor in the gastric antrum dependent of the minor curvature and anterior wall. The histopathological report with hematoxylin and eosin staining demonstrated that the tumor were be compatible with an epithelioid type gastrointestinal stromal tumor (Fig 3), with low mitotic activity and resection edges free of neoplasia. The suspected diagnosis of a GIST tumor was confirmed by its positivity in immunohistochemistry to (C-Kit) – (CD117) (Fig 4).

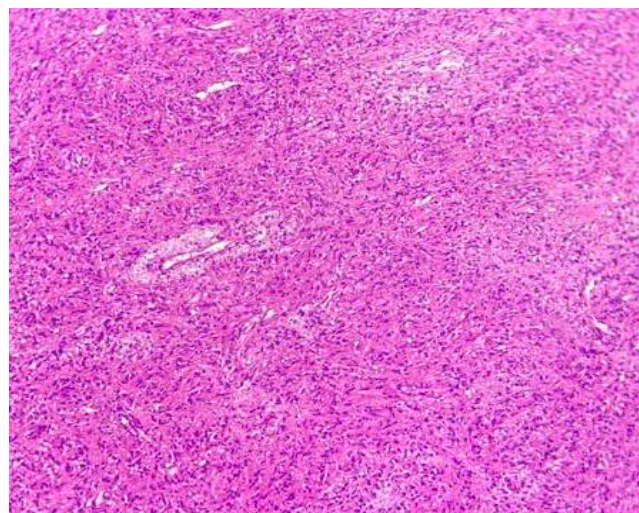


Figure 3. Histopathological staining with hematoxylin and eosin where multiple polymorphic cells with an epithelioid appearance are seen.

Gist Tumor Manifested with Digestive Tract Bleeding: Case Report and Literature Review

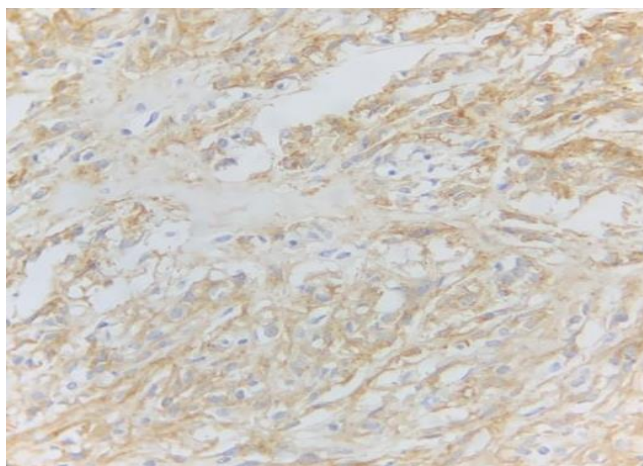


Figure 4. Histopathology with Immunohistochemistry where CD117 (C-kit) shows cytoplasmic immunostaining with a Golgi pattern without evidence of increased mitotic activity.

After evaluation and reporting of complete tumoral resection with resection edges free of neoplasia and non-invasion to surrounding lymph nodes, a complete cure was considered in our patient who, due to being a low-risk GIST tumor it didn't need treatment with tyrosine kinase inhibitors, however, given the high recurrence rate reported in these tumors despite a successful treatment, long-term follow-up were performed.

After 6 months of post-surgical follow-up, the patient was found to be completely asymptomatic with no data suggestive of recurrence.

DISCUSSION

Gastrointestinal stromal tumors constitute a group of tumors that occur very infrequently, with an estimated incidence of approximately 10 cases per million people [5]. They predominate in people between 40 and 80 years of age, the most common age of presentation is 60 years of age with no difference between both sexes [6].

The clinical picture in most of cases are non-specific and it depends of the location and tumoral size [7]; In other cases they present doesn't have symptoms, however when they are symptomatic the condition presents as early satiety, non-specific abdominal pain, sensation of a palpable mass when it is a large tumor or in the case of smaller gastric tumors as

in our case they manifests as anemia of unknown origin or even with melanic evacuations [8]. Less frequently, tumoral rupture, intestinal obstruction and/or perforation may occur [9].

Its spread is generally through the blood and peritoneal routes, the sites with the greatest presence of metastases are the liver and peritoneum, and that's the importance of computed tomography in the diagnosis of the extension of this type of tumors [10].

Laboratory studies are usually non-specific and in the case of imaging studies, computed tomography (CT) and magnetic resonance imaging (MRI) are the first-line studies [11]. GISTs are generally observed as isodense lesions, that sometimes presents intratumoral calcifications; however, despite establishing a presumptive diagnosis, neither of these two is specific.

Therefore, the definitive diagnosis relies in anatomopathological and immunohistochemical studies, which provide the necessary information to differentiate them from other types of neoplasms [12]; Their histopathological characteristics allow them to be classified as spindle cells (70%), epithelioid cells (20%) or a combination of spindle and epithelioid cells [13].

The principal immunohistochemical characteristic for GISTs is that in up to 95% of cases they express the specific tyrosine kinase growth factor, better known as the KIT proto-oncogene, that express CD117, in a lesser proportion they also express CD34, desmin and S-100 [14]. However, there are 5% of cases in which the tumor is negative for CD117, CD34, desmin and S-100; So in these cases additional tests come into role for diagnosis consisting of DOG1 staining, KIT gene mutation or mutations in the platelet growth factor receptor alpha gene (PDGFRA) [15].

The differential diagnosis of GIST is with other types of tumors such as carcinoma, metastatic melanoma, clear cell sarcoma, among others [16].

Table 1. Prognosis of malignancy of gastrointestinal stromal tumors according to size and mitosis per field [24].

<i>Malignancy risk</i>	<i>Tumoral size</i>	<i>Mitosis/Field</i>
<i>Very low</i>	< 2 cm	> 5
<i>Low</i>	2 – 5 cm	< 5
<i>Intermediate</i>	< 5 cm	6 – 10
<i>High</i>	5-10 cm	< 5
	> 5 cm	< 5
	> 10 cm	Any
	Any	> 10

Gist Tumor Manifested with Digestive Tract Bleeding: Case Report and Literature Review

The treatment of choice in non-metastatic GIST is complete surgical resection with safety margins of 1-2 cm, which represents the success in up to 95% of cases [17], always taking care to preserve the tumor capsule. Despite adequate treatment none patient is exempt from tumoral recurrence, hence the importance of close follow-up despite successful resection of the GIST. The recurrence rate depends on the quality of tumor resection, being 40% in patients with a complete tumor resection with surgical margins free of disease and up to almost 100% in patients who present capsular rupture during the procedure [18], so the resections always need to be carried out with special care. With unresectable gastrointestinal stromal tumors, the importance of their positivity in tyrosine kinase expression have an important role in the pathogeny, so the since of inclusion of tyrosine kinase inhibitors these revolutionized the treatment and improved the prognosis of advanced GISTs [19].

Treatment with tyrosine kinase inhibitors consists in neoadjuvant and adjuvant treatment. The assessment of neoadjuvant treatment is generally carried out one month after initiation with a CT to assess the reduction in tumoral size, the perfect time to perform the surgical intervention is between 6-12 months after the start of imatinib, which is the time of maximum response to treatment [20].

The length of treatment, even if it is neoadjuvant or adjuvant, generally maintains for up to 36 months, but in cases of tumoral rupture, due to the high risk of recurrence it can even be maintained for life [21].

The prognosis generally depends on the interaction of three main components: Size, location and mitotic tumoral index [22]. It is considered that from 5 cm in tumor size, as well as a mitotic index greater than 5/50 per field, the risk of generating local and distant metastases are greater [23], so the GISTs are classified according to their potential to generate metastases into four degrees of malignancy (Table 1) [24].

However, there have been cases in which, despite a small tumoral size and low mitotic index these tumors express a malignant behavior are seen, so it is always important to try to provide definitive treatment and adequate follow-up.

The follow-up of low-risk tumors is carried out by CT every six months for five years and those with high or intermediate risk needs a CT every three or four months for the first three years, subsequently every six months until the fifth year and annually for another five years [25].

CONCLUSION

In conclusion, GISTs are tumors that have a very low incidence and that in most of cases have an unspecific presentation, so their diagnostic suspicion is very low. It's especially important in cases when they presents with symptomatology perform a timely diagnostic-therapeutic approach with image studies in order to demonstrate distant dissemination, tumoral resection and histopathological analysis with immunohistochemistry, since it has been seen

that the risk of malignancy and recurrence is variable depending on tumoral size, mitosis per field and the successfully resection with adequate security margins.

Another point to take account is the therapeutic effectiveness of tyrosine kinase inhibitors, so we must not leave aside the use of imatinib as a neoadjuvant or adjuvant treatment to improve the success rates in those tumors who are unresectable or with a high risk of recurrence.

CONFLICT OF INTERESTS

The authors have declared no conflicts of interest.

REFERENCES

- I. Manxhuka-Kerliu, S., Sahatciu-Meka, V., Kerliu, I., Juniku-Shkololli, A., Kerliu, L., Kastrati, M., & Kotorri, V. (2014). Small intestinal gastrointestinal stromal tumor in a young adult woman: a case report and review of the literature. *Journal of medical case reports*, 8, 321. <https://doi.org/10.1186/1752-1947-8-321>
- II. Demetri, G. D., von Mehren, M., Antonescu, C. R., DeMatteo, R. P., Ganjoo, K. N., Maki, R. G., Pisters, P. W., Raut, C. P., Riedel, R. F., Schuetze, S., Sundar, H. M., Trent, J. C., & Wayne, J. D. (2010). NCCN Task Force report: update on the management of patients with gastrointestinal stromal tumors. *Journal of the National Comprehensive Cancer Network : JNCCN*, 8 Suppl 2(0 2), S1–S44. <https://doi.org/10.6004/jnccn.2010.0116>
- III. Castillo Paucar, M., Quingalombo Cargua, G. F., & Garcés García, T. P. (2023). Sangrado digestivo alto secundario a tumor del estroma gastrointestinal (GIST) asociado a linfoma MALT: caso clínico. *Revista Medicina E Investigación Clínica Guayaquil*, 2(2), 41 - 45. <https://doi.org/10.51597/rmicg.v2i2>.
- IV. Mantese G. (2019). Gastrointestinal stromal tumor: epidemiology, diagnosis, and treatment. *Current opinion in gastroenterology*, 35(6), 555–559. <https://doi.org/10.1097/MOG.0000000000000584>
- V. Moreno-Paquentín, Eduardo, Caba Molina, David, Sánchez-García, Jorge, Arrangoiz-Majul, Rodrigo, Cordera-González de Cosío, Fernando, Luque de León, Enrique, Muñoz-Juárez, Manuel, Cruz-González, Efraín, Negrete-Cervantes, Luis Fernando, Valdez-Bocanegra, David Ricardo, & Tamayo-Ochoa, Paulina. (2018). Reporte de caso clínico de un tumor del estroma gastrointestinal (GIST) gigante y revisión bibliográfica. *Cirujano general*, 40(2), 127-132.
- VI. Jones, J. D., Oh, S., Clark, C., & Pawa, R. (2016). A Bleeding Duodenal GIST Masquerading as Refractory Peptic Ulcer Disease. *ACG case reports journal*, 3(4), e189.

Gist Tumor Manifested with Digestive Tract Bleeding: Case Report and Literature Review

- <https://doi.org/10.14309/crj.2016.162>
- VII. Nemeth, K., Williams, C., Rashid, M., Robinson, M., & Rasheed, A. (2015). Oesophageal GIST-A rare breed case report and review of the literature. *International journal of surgery case reports*, 10, 256–259. <https://doi.org/10.1016/j.ijscr.2015.02.023>
- VIII. Judson, I., Bulusu, R., Seddon, B., Dangoor, A., Wong, N., & Mudan, S. (2017). UK clinical practice guidelines for the management of gastrointestinal stromal tumours (GIST). *Clinical sarcoma research*, 7, 6. <https://doi.org/10.1186/s13569-017-0072-8>
- IX. Von Mehren, M., & Joensuu, H. (2018). Gastrointestinal Stromal Tumors. *Journal of clinical oncology : official journal of the American Society of Clinical Oncology*, 36(2), 136–143. <https://doi.org/10.1200/JCO.2017.74.9705>
- X. Fernández-Ruiz M, Cabezas-Palacios MN, Rodríguez-Zarco E, Tato-Varela S. Tumor del estroma gastrointestinal: reporte de un caso. *Ginecol Obstet Mex*. 2016 sept;84(9):607-613.
- XI. Losada M., Héctor, Sanhueza V., Felipe, Klein D., Marcelo, & Becker H., Renato. (2021). GIST duodenal asociado a hemorragia digestiva alta. Reporte de caso. *Revista de cirugía*, 73(2), 212-216. <https://dx.doi.org/10.35687/s2452-45492021002861>
- XII. Gonzalez-Campora, Ricardo & Ramos, Rafael & Vallejo-Benitez, Ana & Marcilla-Plaza, David & Biscuola, Michele & Martínez-Marín, Virginia & Serrano, César & Muñiz, Nadia & Lopez-Guerrero, Jose & Martin-Broto, Javier. (2017). Tumores del estroma gastrointestinal: breve actualización y consenso de la SEAP-SEOM sobre diagnóstico patológico y molecular. *Revista Española de Patología*. 50. [10.1016/j.patol.2016.12.004](https://doi.org/10.1016/j.patol.2016.12.004).
- XIII. Baiomi, A., Abbas, H., & Bhavna, B. (2021). Gastrointestinal Stromal Tumor as a Rare Cause of Abdominal Mass: A Case Report and Literature Review. *Cureus*, 13(3), e14070. <https://doi.org/10.7759/cureus.14070>
- XIV. Poveda, A., García Del Muro, X., López-Guerrero, J. A., Cubedo, R., Martínez, V., Romero, I., Serrano, C., Valverde, C., Martín-Broto, J., & GEIS (Grupo Español de Investigación en Sarcomas/Spanish Group for Sarcoma Research) (2017). GEIS guidelines for gastrointestinal sarcomas (GIST). *Cancer treatment reviews*, 55, 107–119. <https://doi.org/10.1016/j.ctrv.2016.11.011>
- XV. Akahoshi, K., Oya, M., Koga, T., & Shiratsuchi, Y. (2018). Current clinical management of gastrointestinal stromal tumor. *World journal of gastroenterology*, 24(26), 2806–2817. <https://doi.org/10.3748/wjg.v24.i26.2806>
- XVI. Navarrete-Salazar VE, Fierro-Macías AE, Mena-Burciaga VM, Franco-Prieto CM, Gallardo-Loya AF, Martínez-Meraz M. Tumor del estroma gastrointestinal (GIST) de yeyuno: caso clínico. *Rev Med Inst Mex Seguro Soc*. 2020;58 (1):66-75.
- XVII. Martin-Broto, J., Martinez-Marín, V., Serrano, C., Hindi, N., López-Guerrero, J. A., Biscuola, M., Ramos-Asensio, R., Vallejo-Benítez, A., Marcilla-Plaza, D., & González-Cámpora, R. (2017). Gastrointestinal stromal tumors (GISTs): SEAP-SEOM consensus on pathologic and molecular diagnosis. *Clinical & translational oncology : official publication of the Federation of Spanish Oncology Societies and of the National Cancer Institute of Mexico*, 19(5), 536–545. <https://doi.org/10.1007/s12094-016-1581-2>
- XVIII. Enodien, B., Hendie, D., Müller, T., Taha-Mehlitz, S., Frey, D. M., & Taha, A. (2023). Gastrointestinal Stromal Tumor (GIST): A Remarkable Case Report and Literature Review. *Cureus*, 15(3), e35931. <https://doi.org/10.7759/cureus.35931>
- XIX. Ferrer Robaina, H., Rodríguez Cruz, Y., Mesa Izquierdo, O., Zayas Díaz, L., & Blanco Amaro, E. (2017). Tumor de estroma gastrointestinal en intestino delgado. *Revista Cubana de Cirugía*, 56(2), 88-94.
- XX. Gheorghe, M., Predescu, D., Iosif, C., Ardeleanu, C., Băcanu, F., & Constantinoiu, S. (2014). Clinical and therapeutic considerations of GIST. *Journal of medicine and life*, 7(2), 139–149.
- XXI. Alanis-Lara J, Castro-Villamour AR, Bravo-Ontiveros F, Arroyo-Hernández G, Klug-Falicoff M. Tumores del estroma gastrointestinal; a propósito de un caso en el yeyuno. *Anales de Radiología México* 2015;14:108-116.
- XXII. Pérez Tauriaux, O., & González Bernardo, R. (2015). Tumor del estroma gastrointestinal de localización gástrica. *MEDISAN*, 19(2).
- XXIII. Delgado Vascones, D. M., & Coloma Exeni, D. A. (2022). Tumor del estroma gastrointestinal (GI) reporte de un caso. *Ciencia Latina Revista Científica Multidisciplinar*, 5(6), 14285-14292. https://doi.org/10.37811/cl_rcm.v5i6.1399
- XXIV. Parab, T. M., DeRogatis, M. J., Boaz, A. M., Grasso, S. A., Issack, P. S., Duarte, D. A., Urayeneza, O., Vahdat, S., Qiao, J. H., & Hinika, G. S. (2019). Gastrointestinal stromal tumors: a comprehensive review. *Journal of gastrointestinal oncology*, 10(1), 144–154. <https://doi.org/10.21037/jgo.2018.08.20>
- XXV. Landell Cruz, J., & Martínez Velázquez, C. (2016). Tumor del estroma gastrointestinal del estomago. *Revista Electrónica Dr. Zoilo E. Marinello Vidaurreta*, 41(8).