

Modified McLaughlin Procedure on Locked Posterior Shoulder Dislocation: A Case Report

Kenny Yulian^{1*}, Gusti Ngurah Putra Stanu², Made Agus Maharjana²

¹ Medical Doctor, Hang Tuah University, Surabaya, Indonesia

² Department of Orthopedic Surgery, Udayana Army Hospital, Denpasar, Bali

ABSTRACT

Posterior shoulder dislocation is a rare and often misdiagnosed case, and returning the stability of the shoulder and preventing recurrent dislocations are key in improving patient's quality of life. A 67-year-old male presented with pain, stiffness, and deformity in his right shoulder for the past month. Shoulder and upper arm were in adduction and internal rotation, and abnormal mass of the humeral head was palpated on the posterior shoulder. Shoulder range of motion was severely limited. Modified McLaughlin procedure was performed, followed by immobilization for 2 weeks after surgery. The patient's mid-term outcome following the modified McLaughlin procedure showed normal shoulder function, with no pain or limitations. This result is likely due to the more stable bony fixation achieved through bone-to-bone union provided by the modified McLaughlin procedure. There were no signs of nerve injury, and no avascular necrosis was observed on the shoulder radiograph.

KEYWORDS: Joint, Posterior Shoulder Dislocation, Modified McLaughlin

ARTICLE DETAILS

Published On:
03 December 2024

Available on:
<https://ijmscr.org/>

BACKGROUND

Posterior shoulder dislocation is a rare case in orthopaedic practice, constituting <4 % of all shoulder dislocations, causing this condition to often be misdiagnosed and neglected ¹.

Up to 79% of the cases are diagnosed after the injury has become chronic and the shoulder has been locked. This is especially true in developing countries, where multiple factors such as degree of education, socioeconomics, and limited utilization of advanced radiographic imaging (such as CT-Scan and MRI) make the diagnosis of posterior shoulder dislocation even more challenging.

CASE REPORT

A 67-year-old male presented to the clinic with complaints of pain, stiffness, and deformity in his right shoulder. The patient has experienced these symptoms since a motor vehicle accident a month ago, in which he fell off his motorcycle, landing on the right side of his body with his right arm abducted and externally rotated. Immediately following the accident, the patient felt pain and swelling on his right shoulder and upper arm, and noticed a deformity on his rear shoulder. The patient went to a local traditional massage therapist where his upper arm and shoulder are massaged, not recognizing the injury that had happened to his right shoulder. With no improvement whatsoever on his

symptoms, the patient went to a general practitioner where conventional x-ray of the shoulder was done. The patient was then prescribed analgesics for the pain. After a month with no improvement of the symptoms other than the swelling, the patient went to the public health center and was referred to an orthopaedic surgeon.

On local examination of the right shoulder, the shoulder and upper arm were found to be in adduction and internal rotation, held close to the body. An abnormal mass of the humeral head was palpated on the posterior shoulder. The range of motion of the shoulder was severely limited (Fig. 1). The patient was unable to rotate his arm externally, and could perform abduction and anterior flexion of the shoulder only less than 10°. Muscle wasting and prominent acromion were also observed. CT scan of the shoulder showed evidence of posterior shoulder dislocation with the presence of reverse hill sachs defect locked into the glenoid. The hill sachs defect was measured to be 33% of the articular surface. The patient was diagnosed with locked posterior shoulder dislocation, and was subsequently prepared for surgery.

Modified McLaughlin Procedure on Locked Posterior Shoulder Dislocation: A Case Report

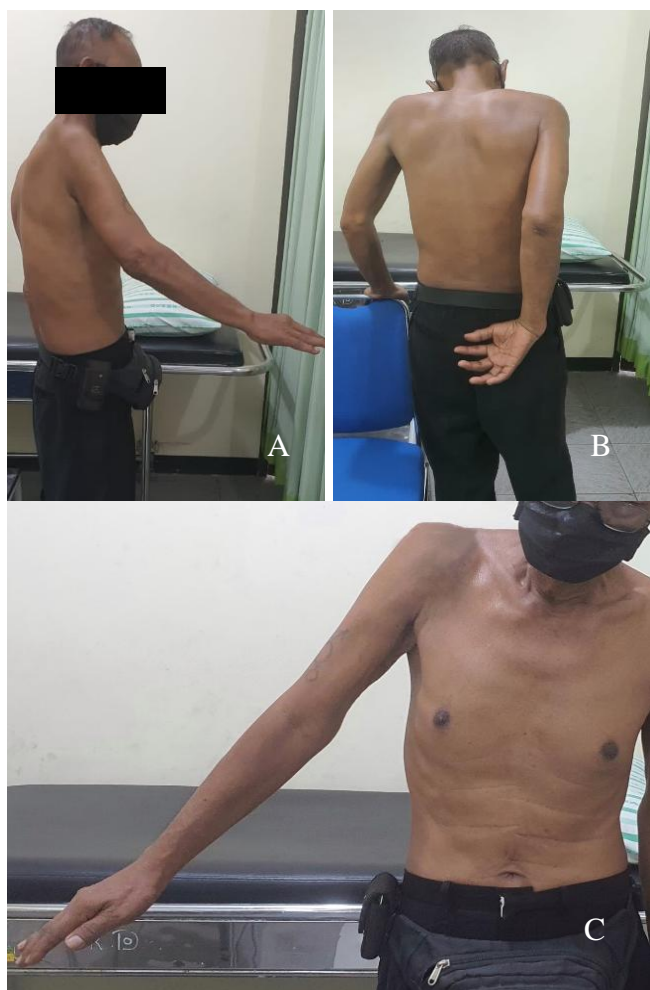

Figure 1. The patient presented with limitation of a) anterior flexion, b) internal rotation, and c) shoulder abduction of the right shoulder

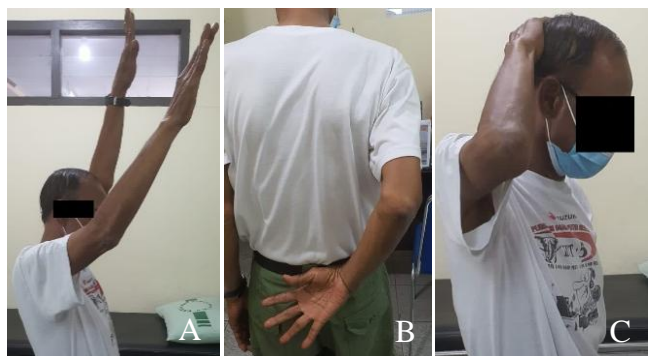


Figure 2. On 8 weeks follow up, the patient demonstrated significant improvement in a) anterior flexion, b) internal rotation, and c) shoulder abduction of the right shoulder

The patient was kept under general anesthesia, and positioned in the beach-chair position. Reduction of the humeral head was then performed, followed by evaluation of post-reduction stability. The patient's shoulder was unstable after reduction, therefore modified McLaughlin procedure was

performed. The deltopectoral approach to the proximal humerus was used. A longitudinal incision was made along the deltopectoral groove, then the short head of the biceps and coracobrachialis were retracted medially, exposing the shoulder joint. Reverse hill sachs lesion was identified on the humeral head, and osteotomy was done on the lesser tuberosity along with the attached subscapularis tendon, followed by arthrotomy at proximal two-thirds of the subscapularis. Fibrous tissue covering the void joint was identified and then removed to visualize the glenoid bone. The lesser tuberosity was attached into the defect of the humeral head, and fixated using two cannulated screws. Tenodesis of the long head of biceps was done to prevent instability of the tendon following osteotomy of the lesser tuberosity. The shoulder was then evaluated for stability, where the result was satisfactory. The shoulder was then immobilized using an arm sling for 2 weeks. The patient was advised to avoid heavy lifting and rigorous activity of the right shoulder until union of the lesser tuberosity was seen on radiographic evaluation. The patient had satisfactory outcome on 8 weeks follow up after surgery, with significant improvement in mobility and pain (Fig. 2). The patient's shoulder was evaluated using Constant-Murley score on mid-term (2 years) follow up, with a constant score of 94 on 2 years after surgery (Fig. 3). No pain or limitation in shoulder range of motion were reported. There were also no signs of nerve injury on physical examination. Plain radiographs of the shoulder showed no complications such as avascular necrosis.

DISCUSSION

Posterior shoulder dislocation occurs when the force of the internal rotators is greater than the external rotators, causing the humeral head to move superiorly and posteriorly. This is most commonly caused by anterior trauma to an abducted and externally rotated shoulder. Other common causes are seizures and electric shocks, which is an emergency and requires urgent treatment therefore causing the presence of posterior shoulder dislocation to be overlooked^{2,3}. For neglected posterior shoulder dislocations, especially those with hill sachs defect greater than 25% of articular surface, closed reduction alone has been proven to be highly unsuccessful, and a more stable surgical repair of the shoulder must be achieved⁴. The modified McLaughlin procedure can be performed using basic orthopedic surgical tools and may provide more stable bony fixation through bone-to-bone union. This is particularly useful in developing countries where advanced tools are rarely accessible and expensive. The modification of the McLaughlin procedure offers additional support and stability, especially for patients with neglected injuries older than three weeks⁵.

Modified McLaughlin Procedure on Locked Posterior Shoulder Dislocation: A Case Report

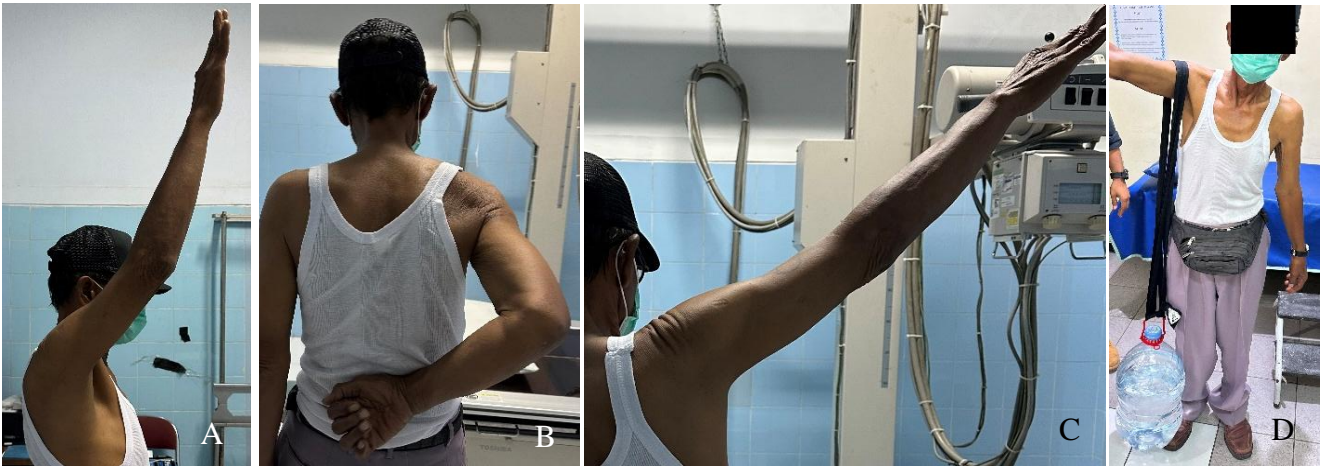

Figure 3. On 2 years follow up, the patient scored 94 on the Constant Murley score and demonstrated excellent a) anterior flexion, b) internal rotation, c) abduction of the right shoulder and d) excellent power with weight applied on the right shoulder

CONCLUSION

For patients with locked posterior shoulder dislocation, restoring shoulder stability and preventing recurrent dislocations are crucial for improving quality of life. It is important to achieve not only short-term relief but also mid-term and long-term stability. The outcome for the patient following the modified McLaughlin procedure demonstrated normal shoulder function with no pain or limitations, as indicated by the constant score. There were no signs of nerve injury, and no avascular necrosis was reported in the shoulder radiograph.

Compliance with Ethical Standarts

Ethics statement This study was approved by the Ethics Committee of Udayana Army Hospital in accordance with the ethical standards laid down in the 1964 WMA Declaration of Helsinki.

Conflict of interest There are no conflict of interest

Declaration of patient consent The authors confirm that informed consents (Consent to Participate and Consent to Publish) were obtained from all participants of this study.

Data Availability Statement The data generated during the current study are available from the corresponding author on reasonable request.

REFERENCES

- I. Basal, O., Dincer, R., & Turk, B. (2017). Locked Posterior Dislocation of the Shoulder: A Systematic Review. *EFORT Open Reviews*, 3, 15-23.
- II. Aydin, N., Kayaalp, M. E., Asansu, M., & Karaismailoglu, B. (2019). Treatment Options for Locked Posterior Shoulder Dislocations and Clinical Outcomes. *EFORT Open Reviews*, 4, 194-200.
- III. Robinson, C. M., Seah, M., & Akhtar, M. A. (2011). The Epidemiology, Risk of Recurrence, and Functional Outcome After an Acute Traumatic Posterior Dislocation of the Shoulder. *The Journal of Bone and Joint Surgery*, 93A, 1605-1613.
- IV. Paparoidamis, G., Iliopoulos, E., Narvani, A. A., Levy, O., Tsiridis, E., & Polyzois, I. (2021). Posterior Shoulder Fracture-Dislocation: A Systematic Review

of the Literature and Current Aspects of Management. *Chinese Journal of Traumatology*, 24, 18-24.

- V. Spencer, E. E., & Brems, J. J. (2005). A Simple Technique for Management of Locked Posterior Shoulder Dislocations: Report of Two Cases. *Journal of Shoulder and Elbow Surgery*.